

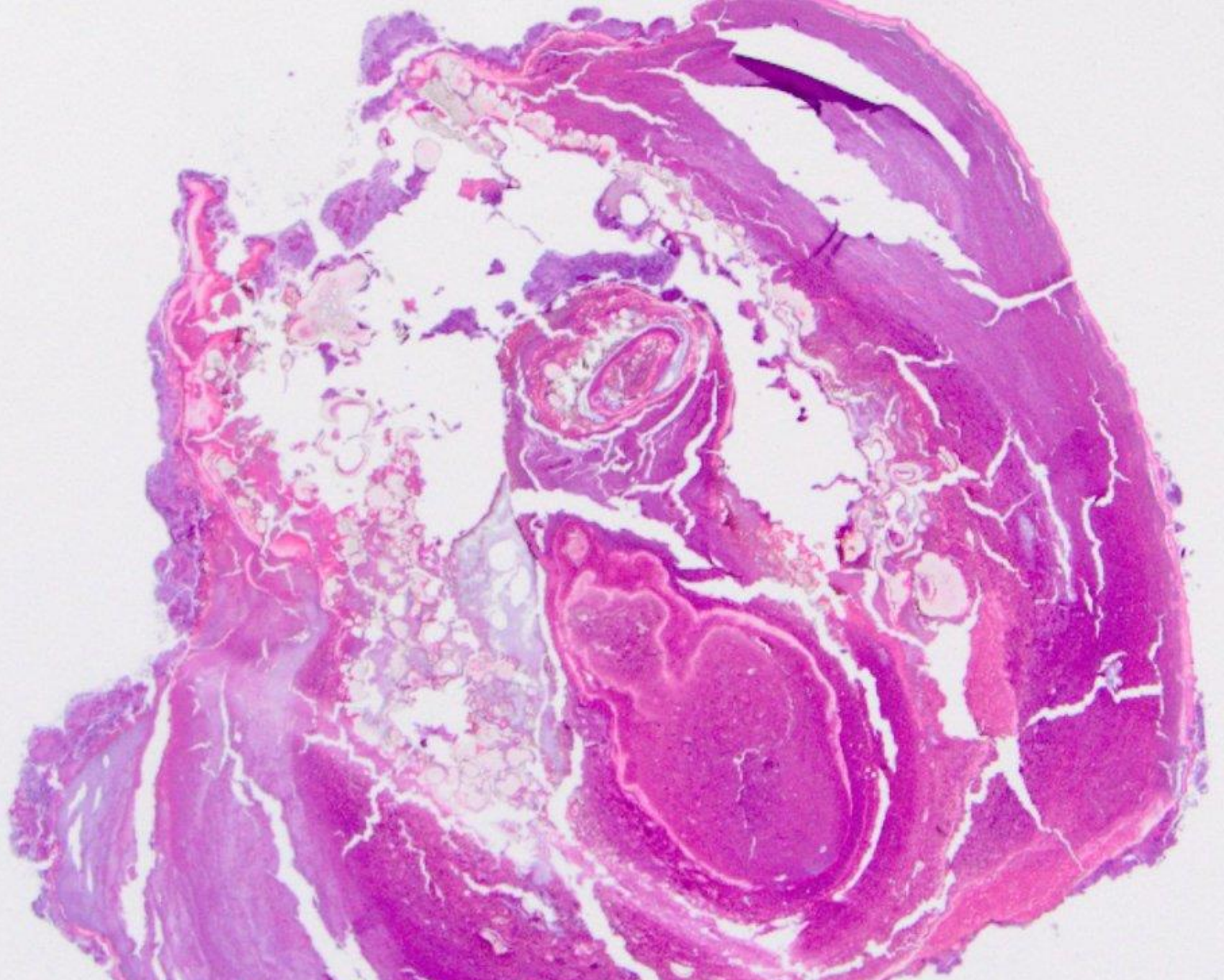
# Oral Histopathology

## Series 29

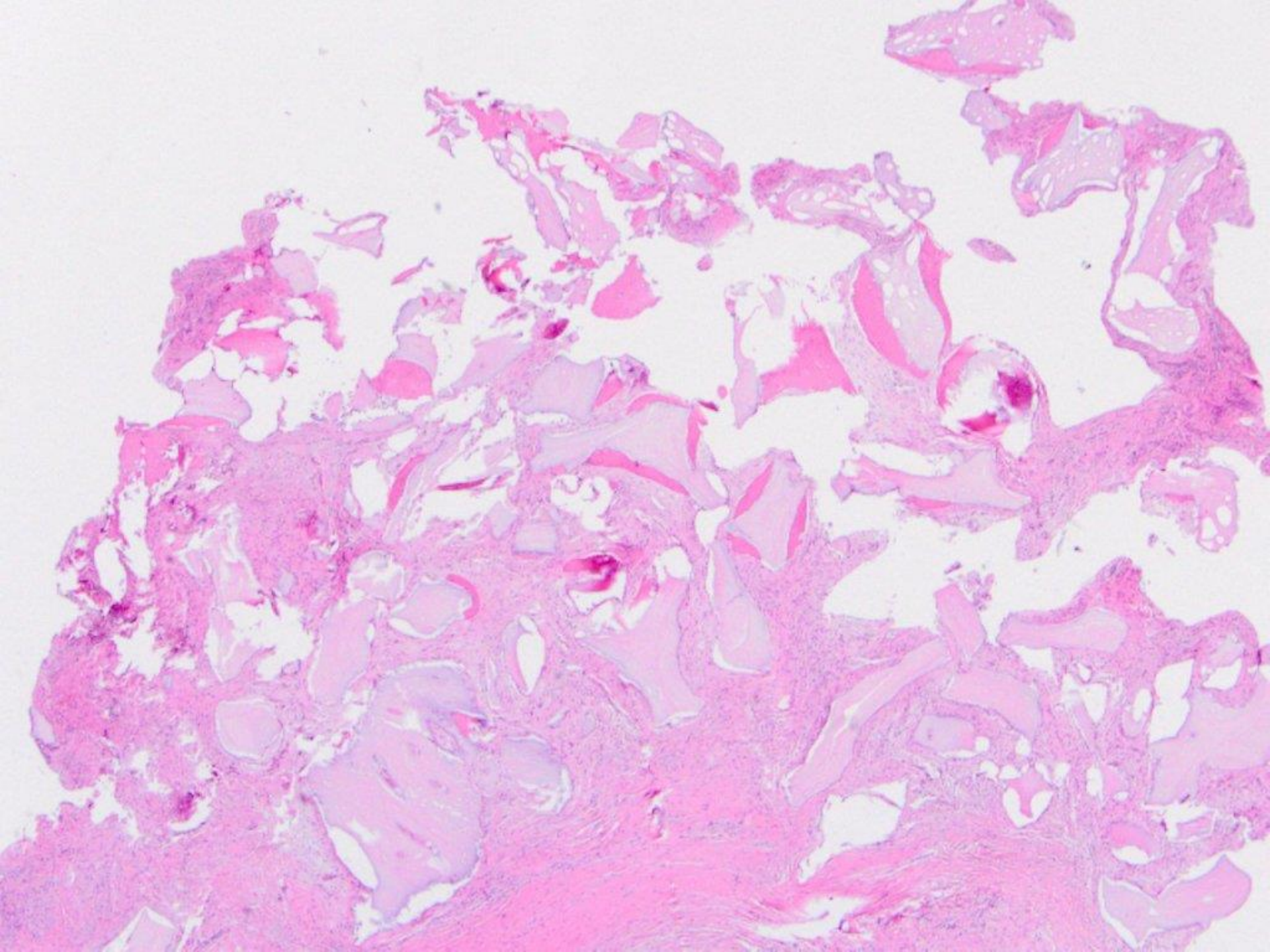
**DAVID E. KLINGMAN, DMD**

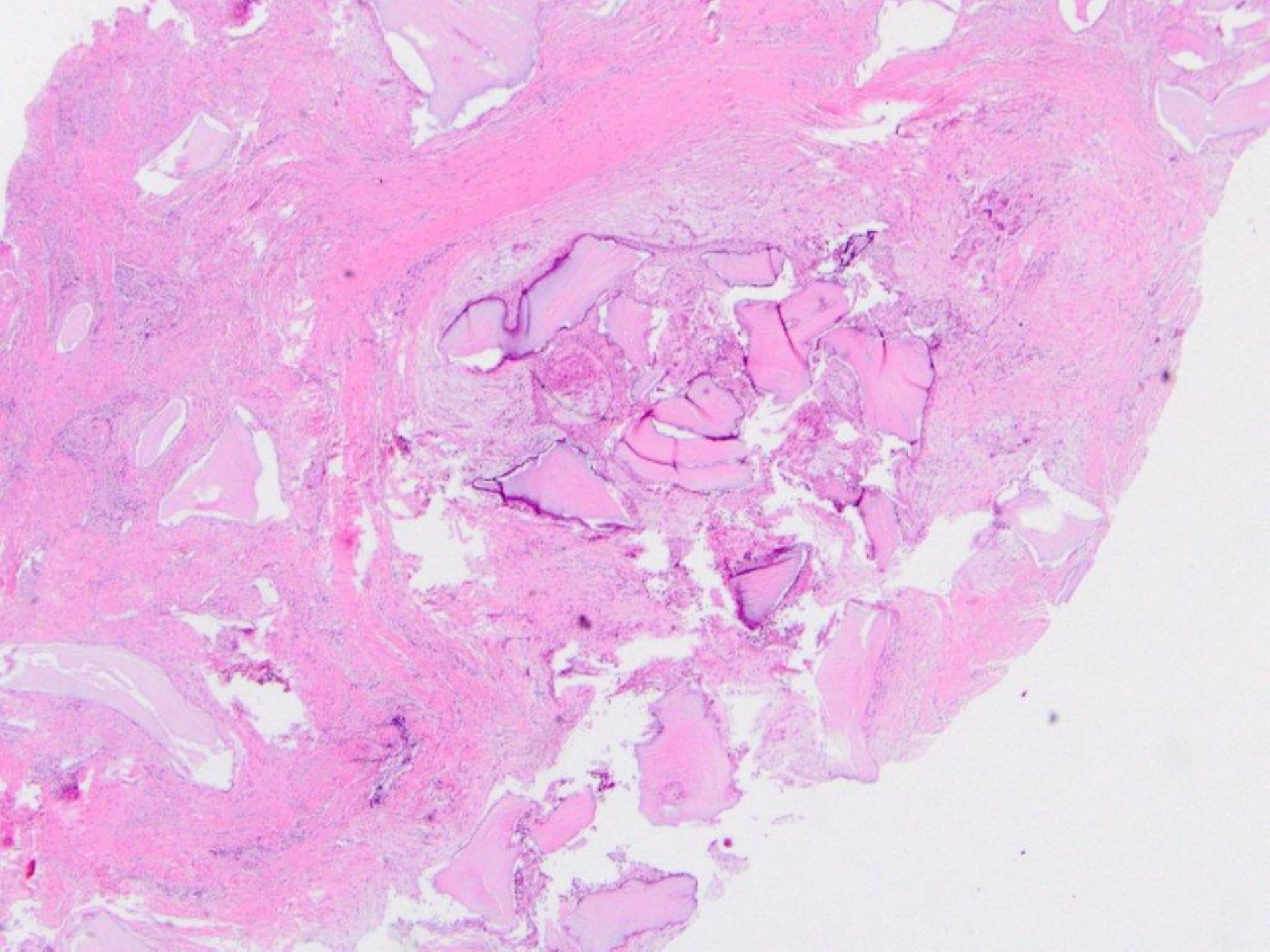
*Diplomate, American Board of Oral and Maxillofacial Pathology*

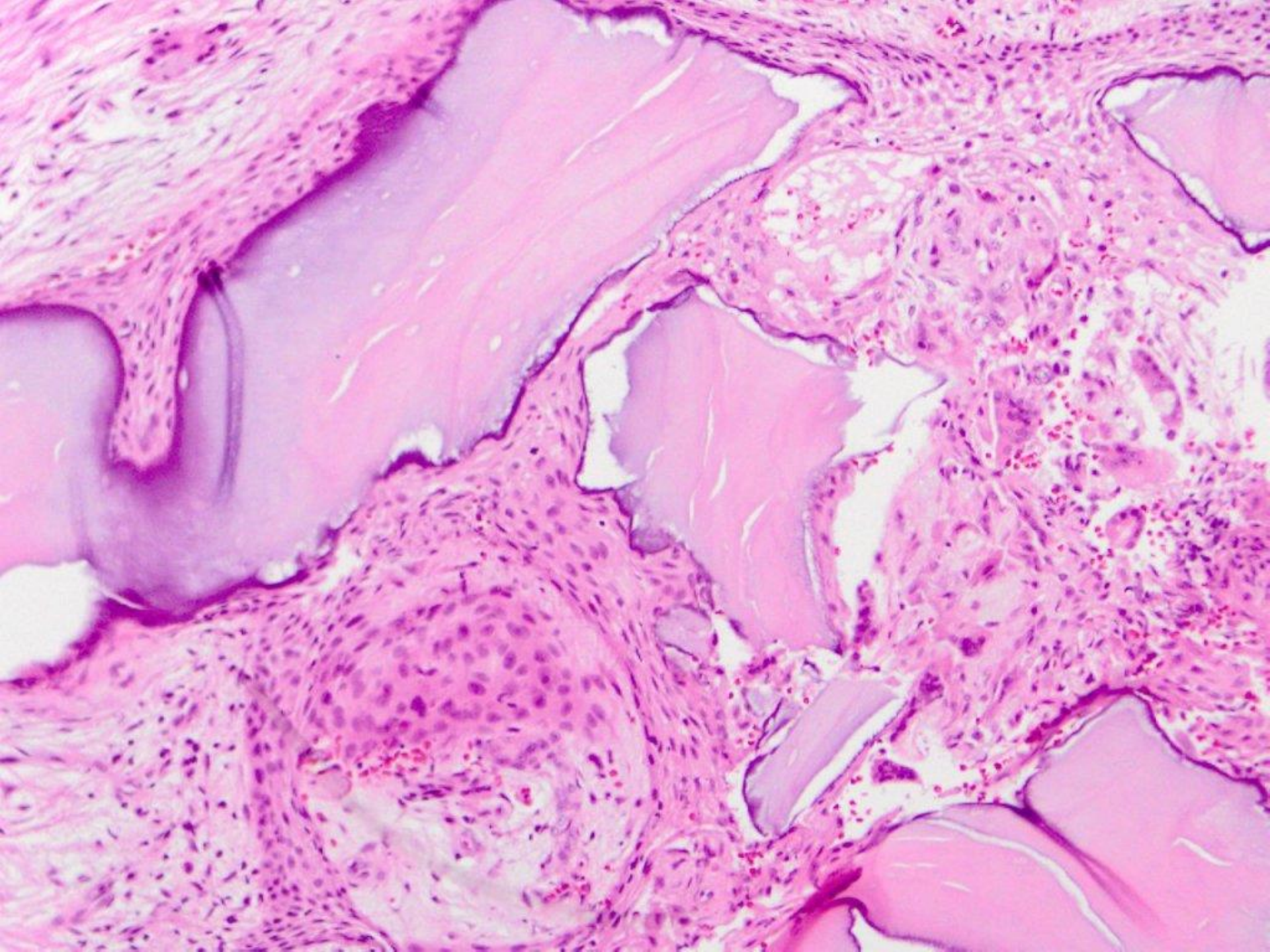
*Diplomate, American Board of General Dentistry*

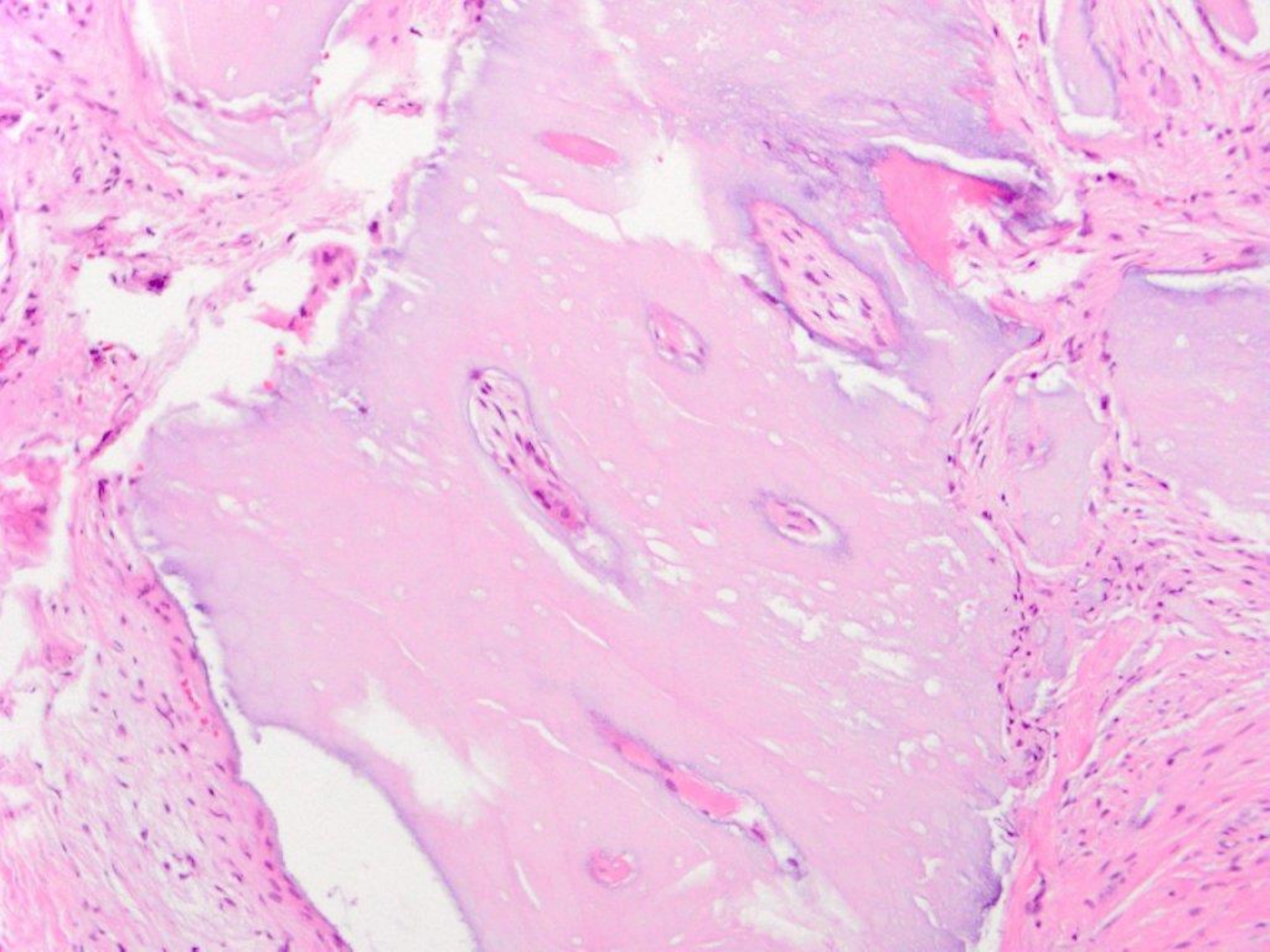


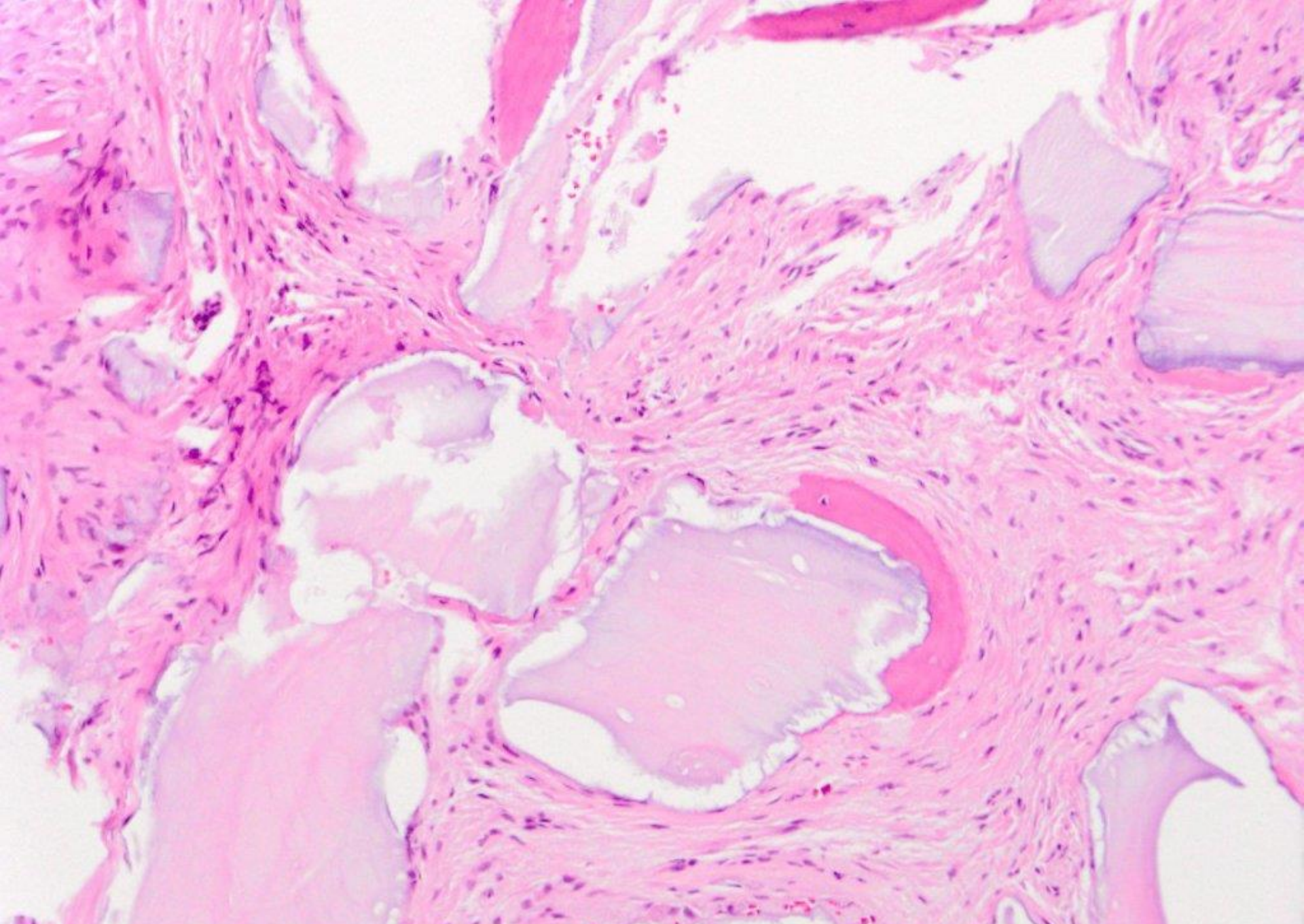
sialolith (this one was from Stensen's duct)



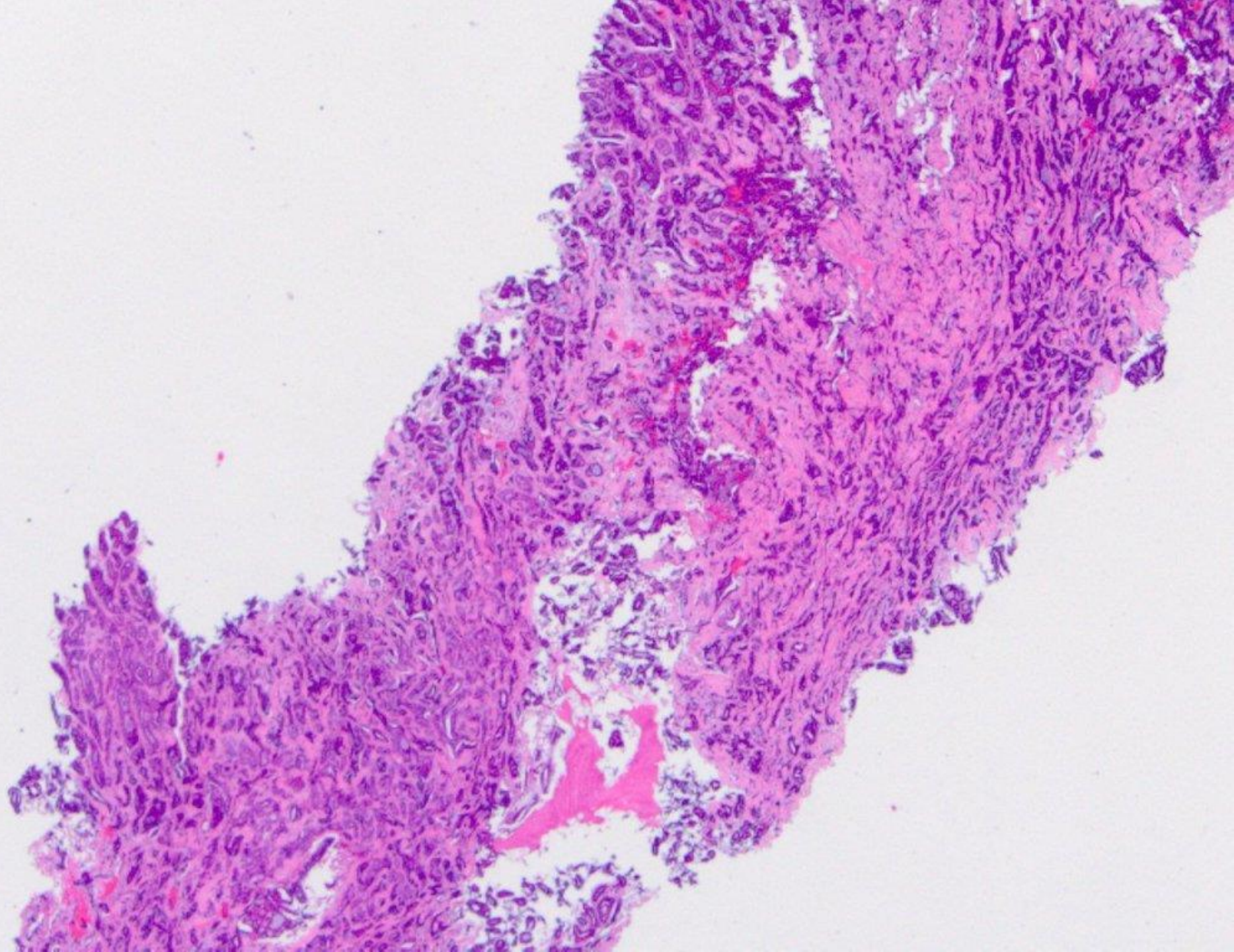




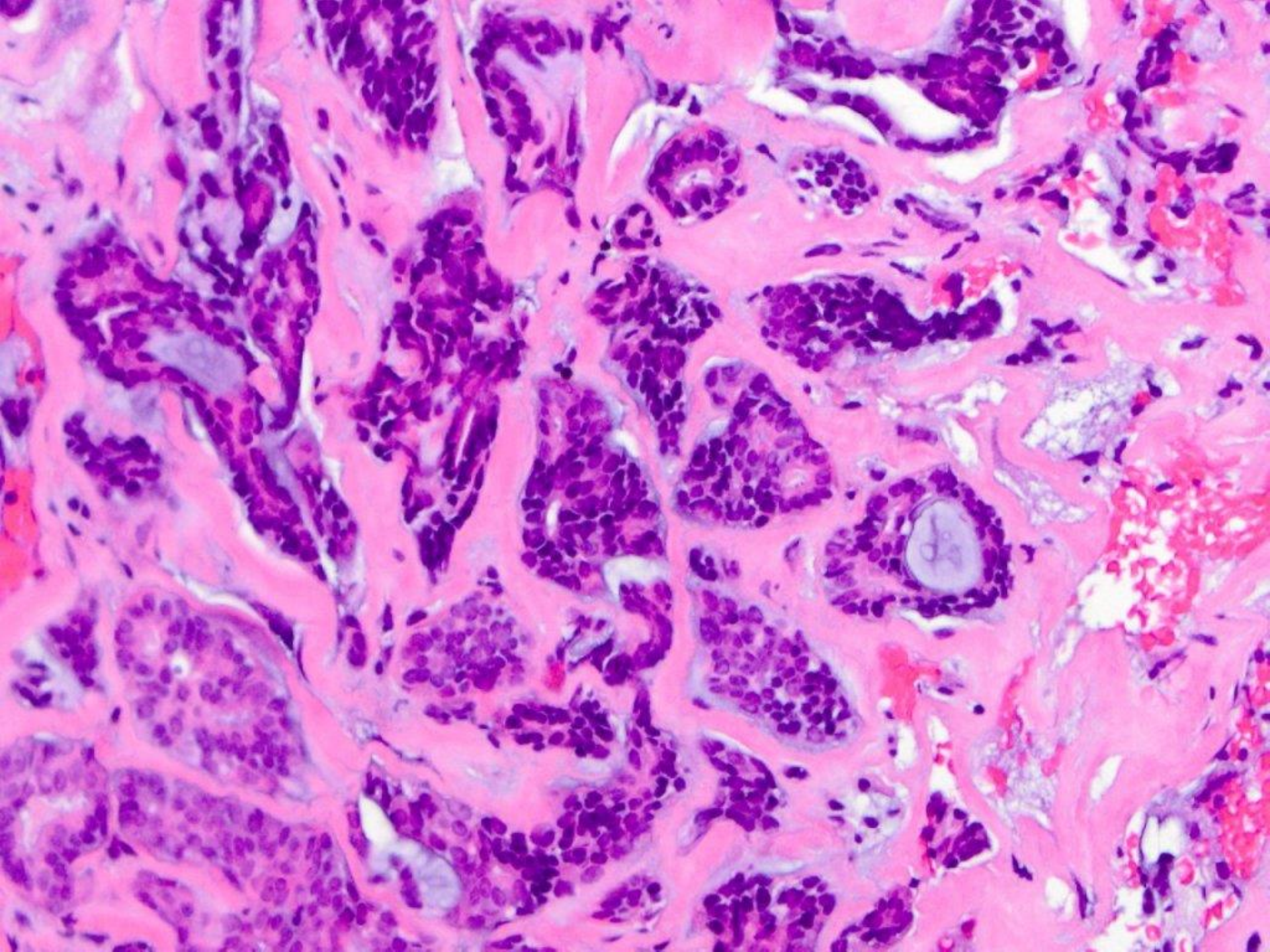


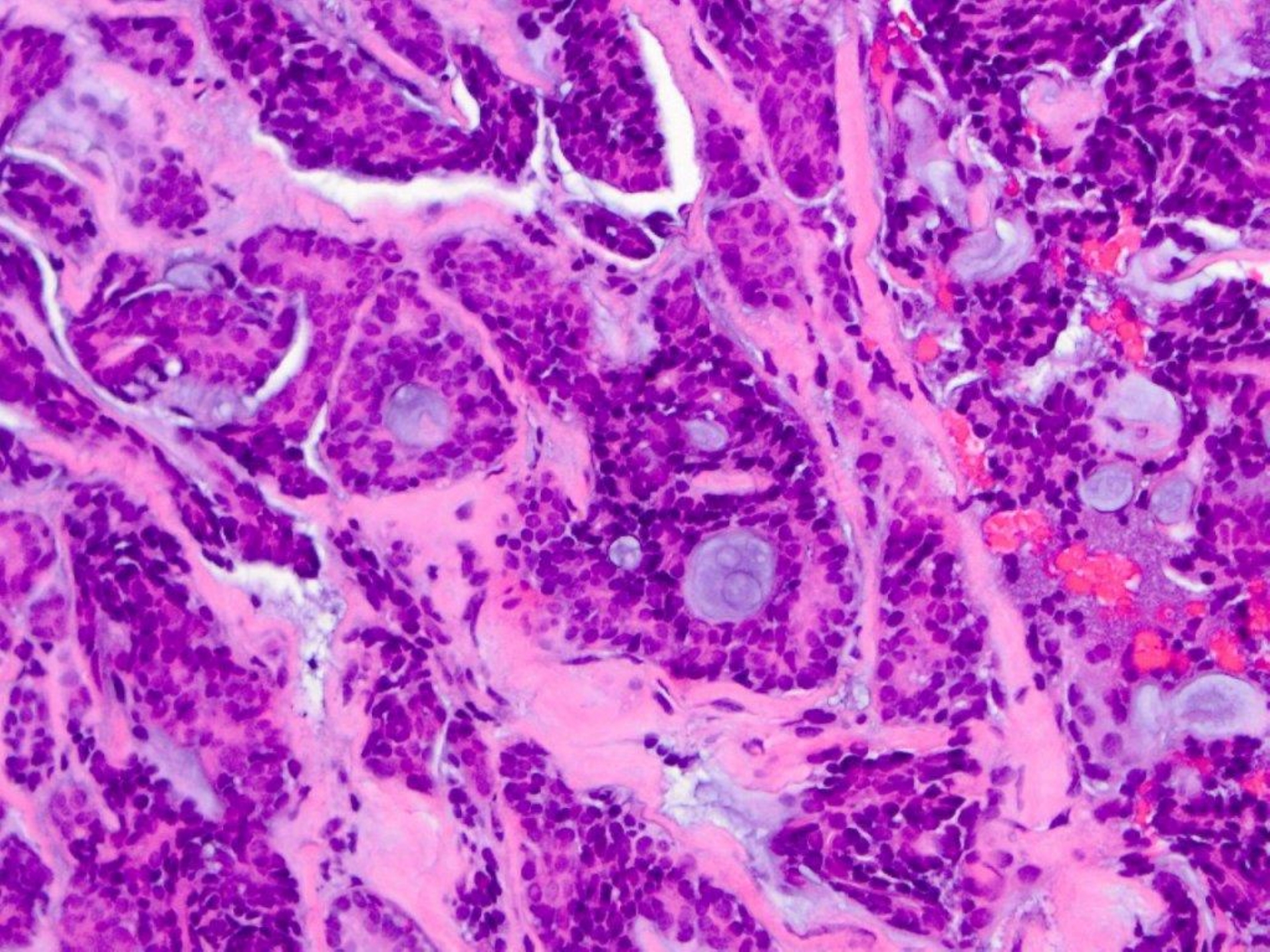


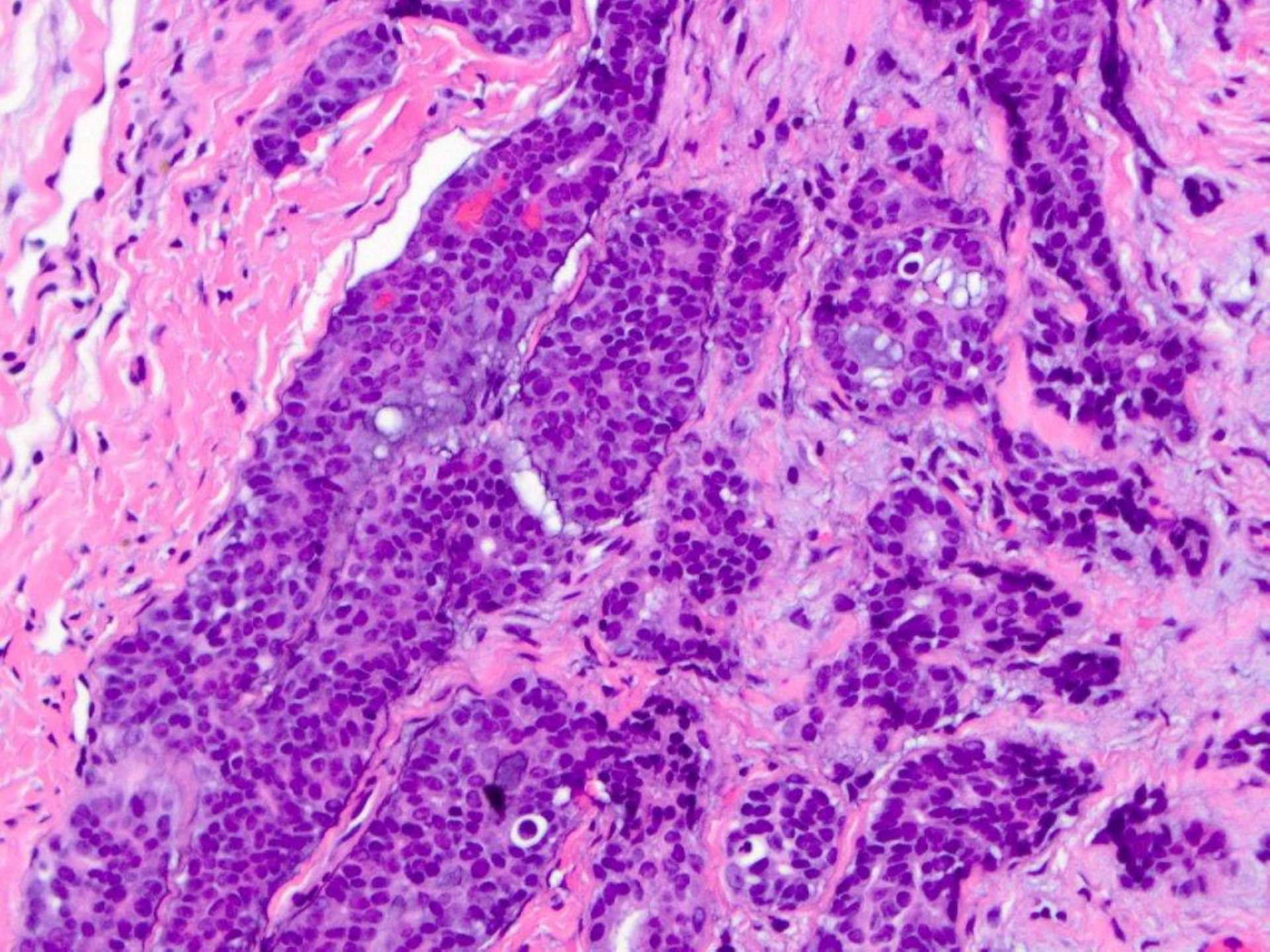
foreign body reaction to graft material (note: bone forming around graft)

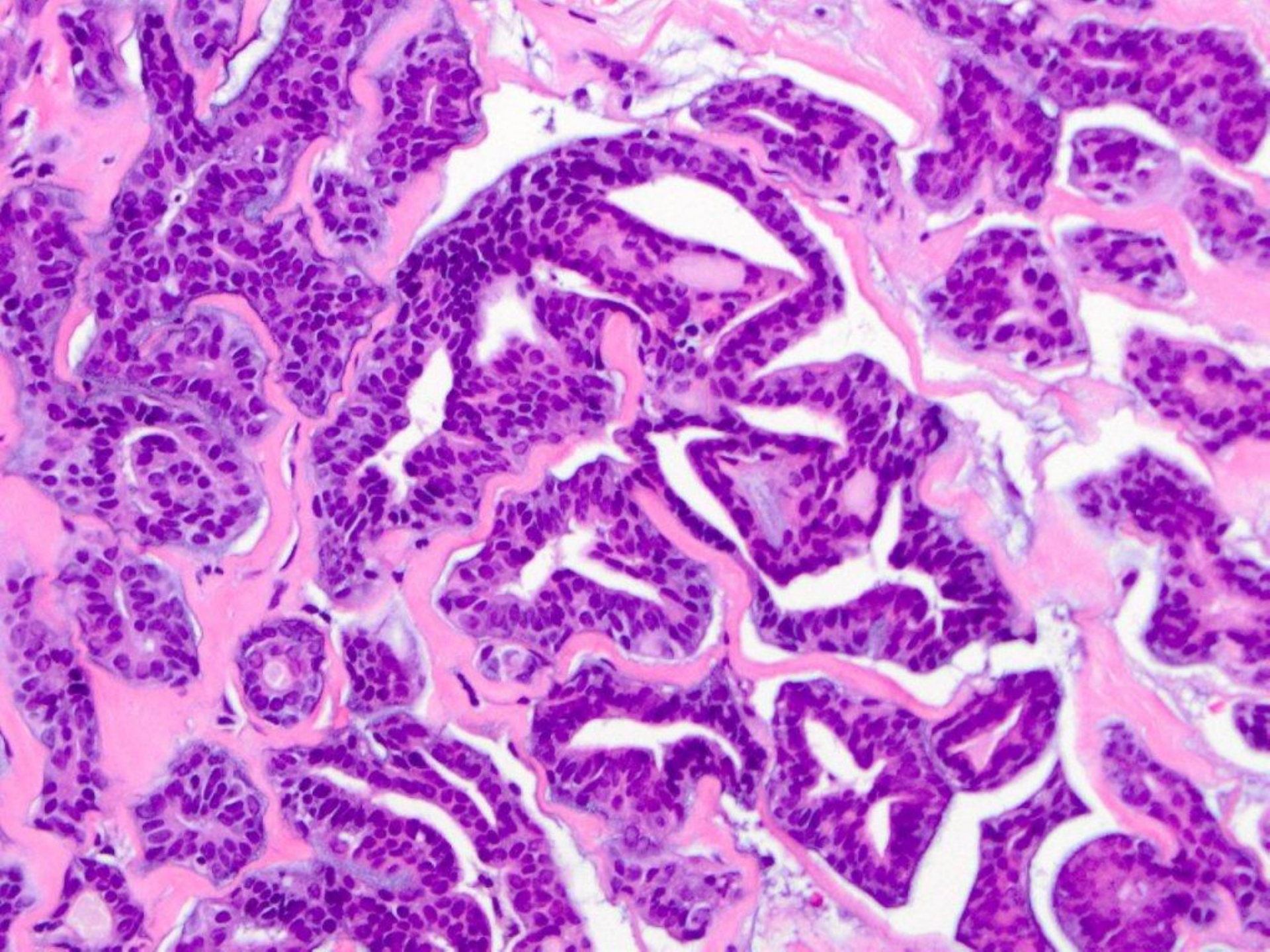


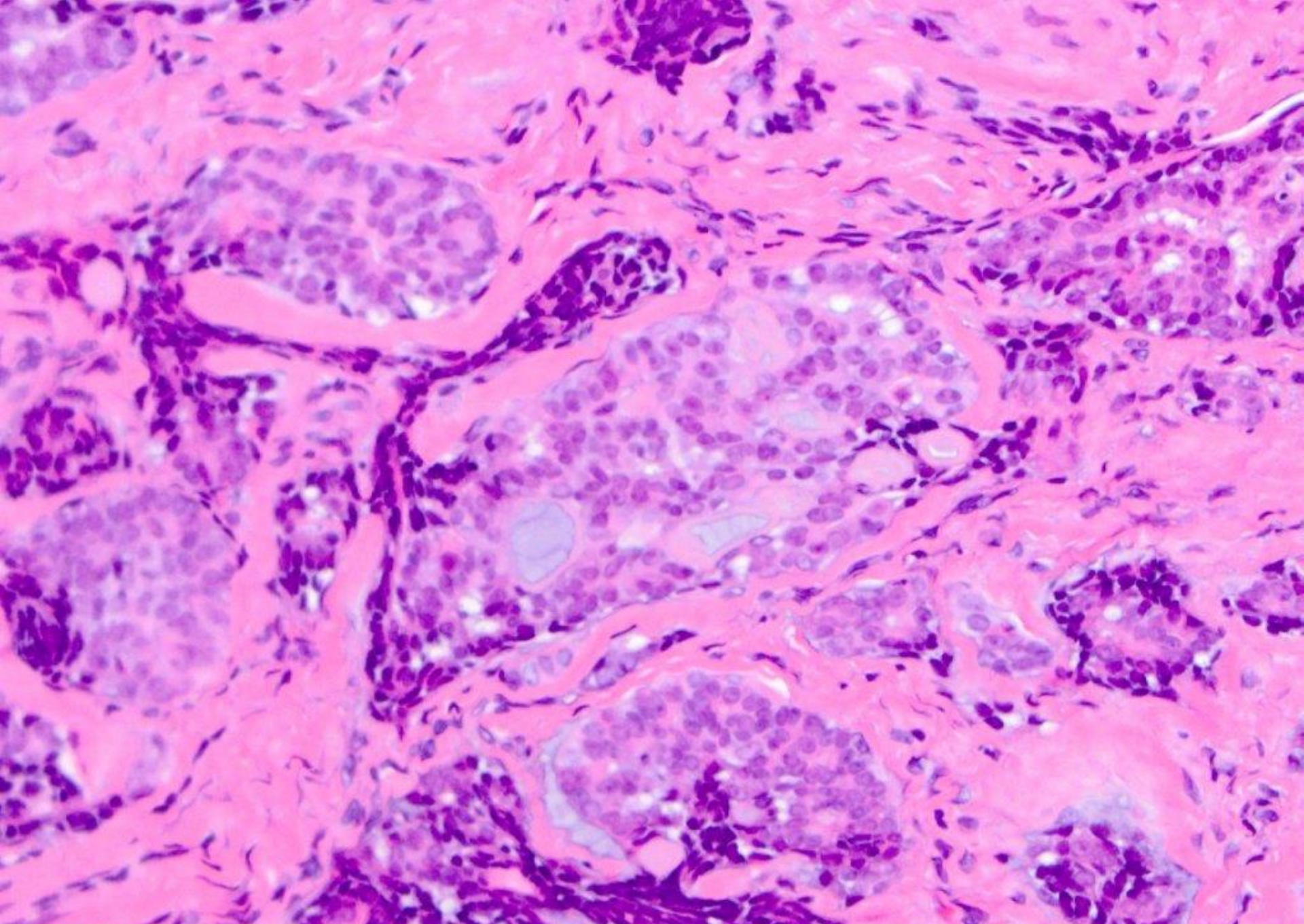




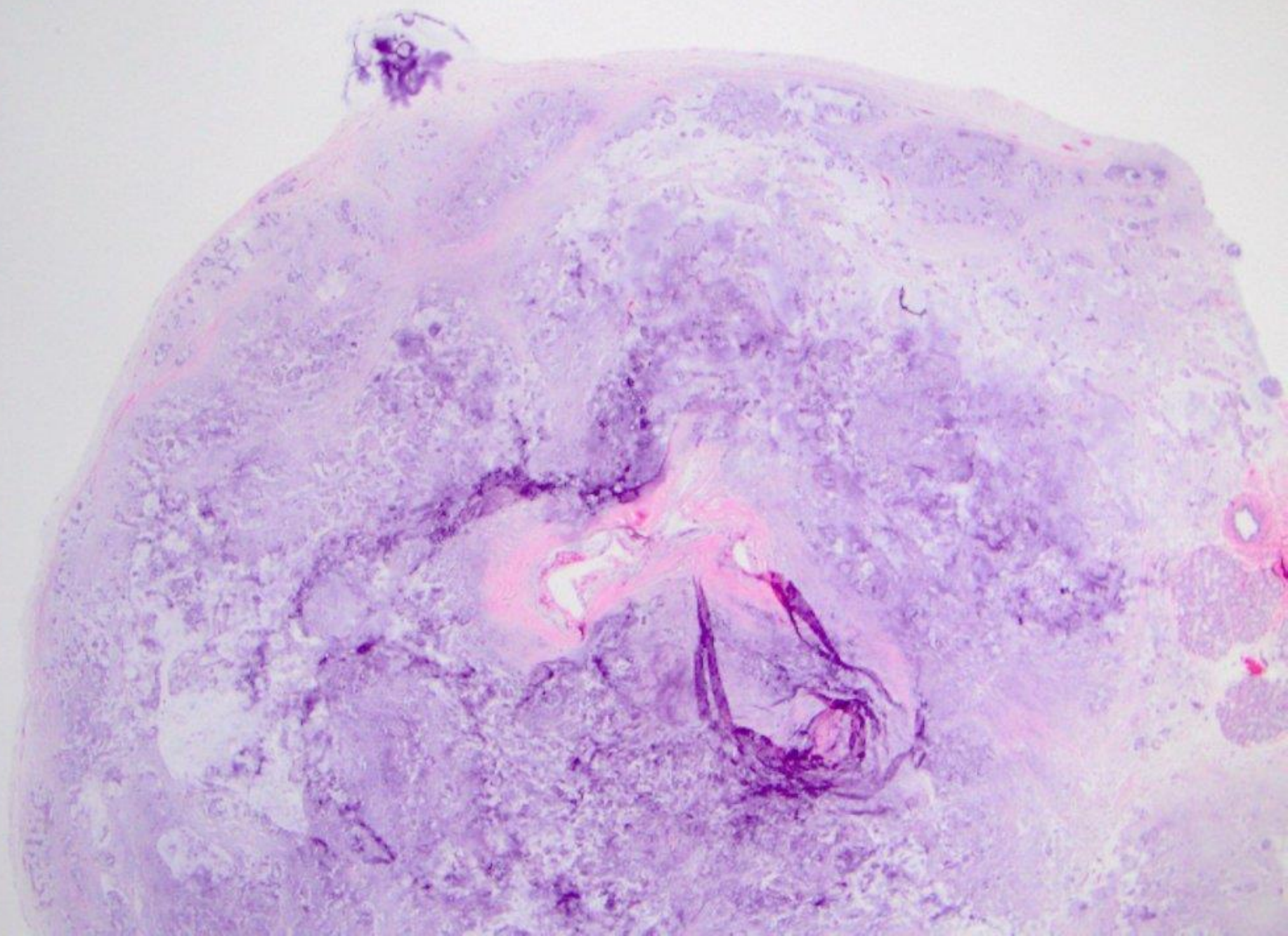


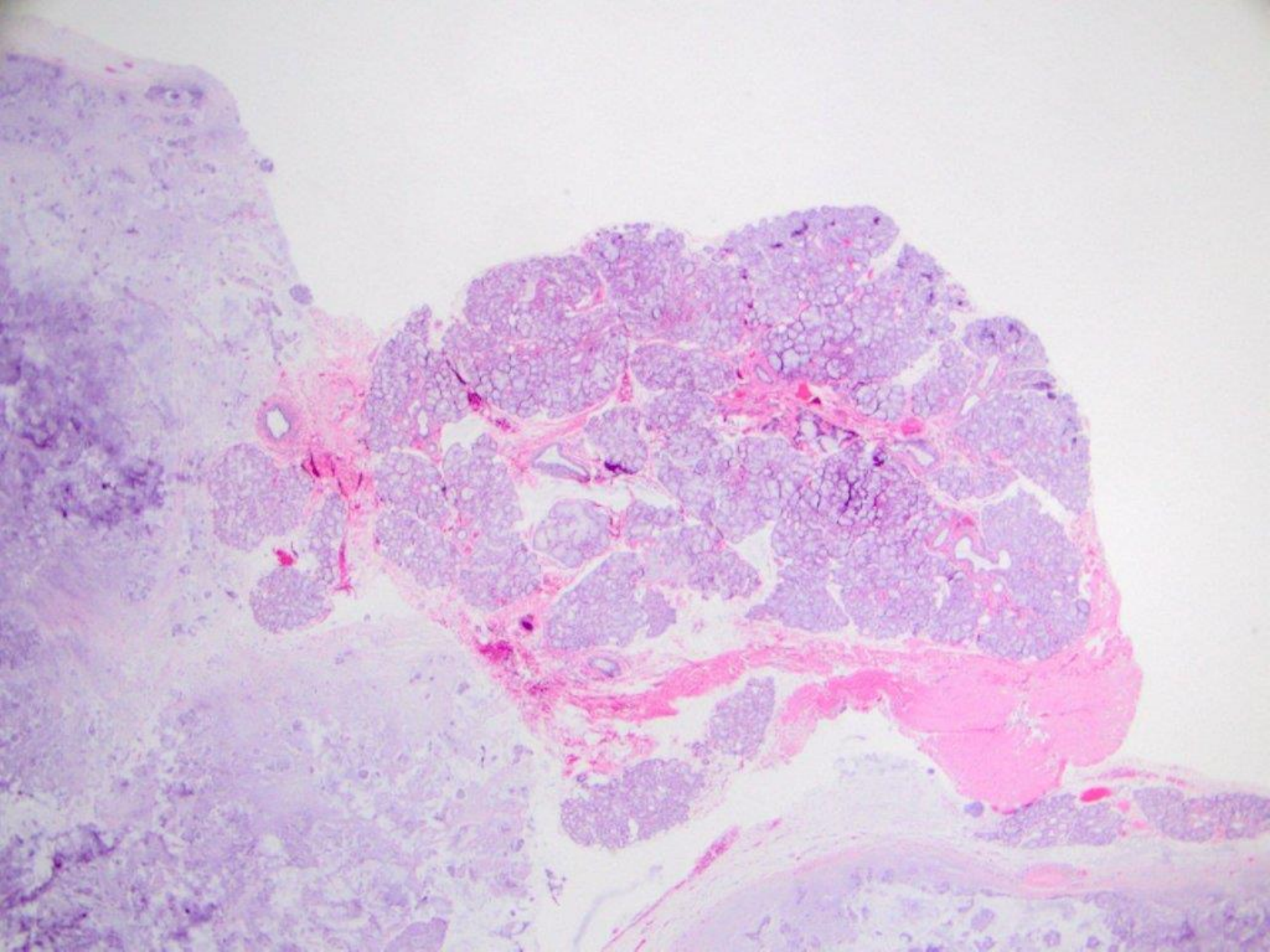


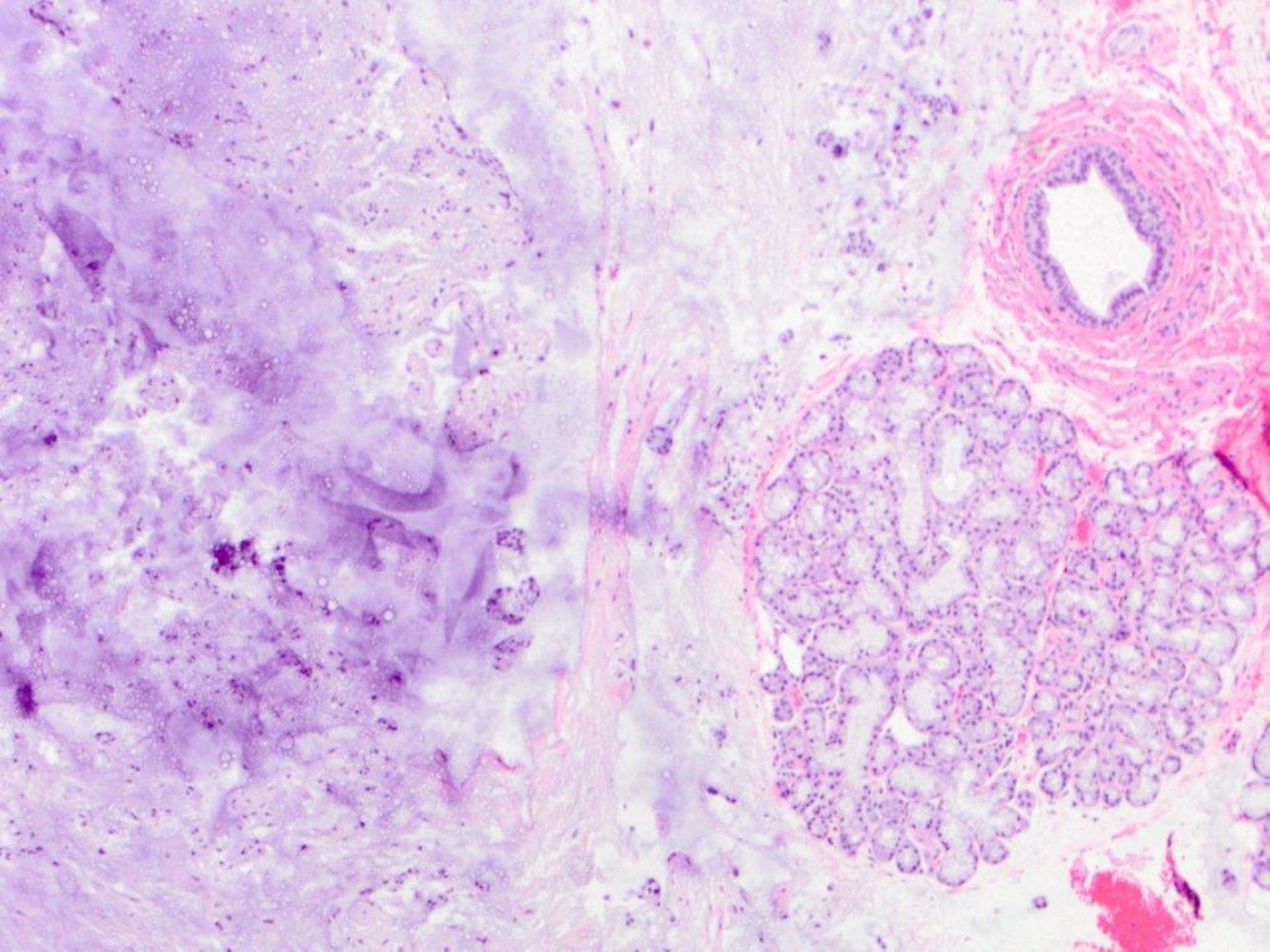




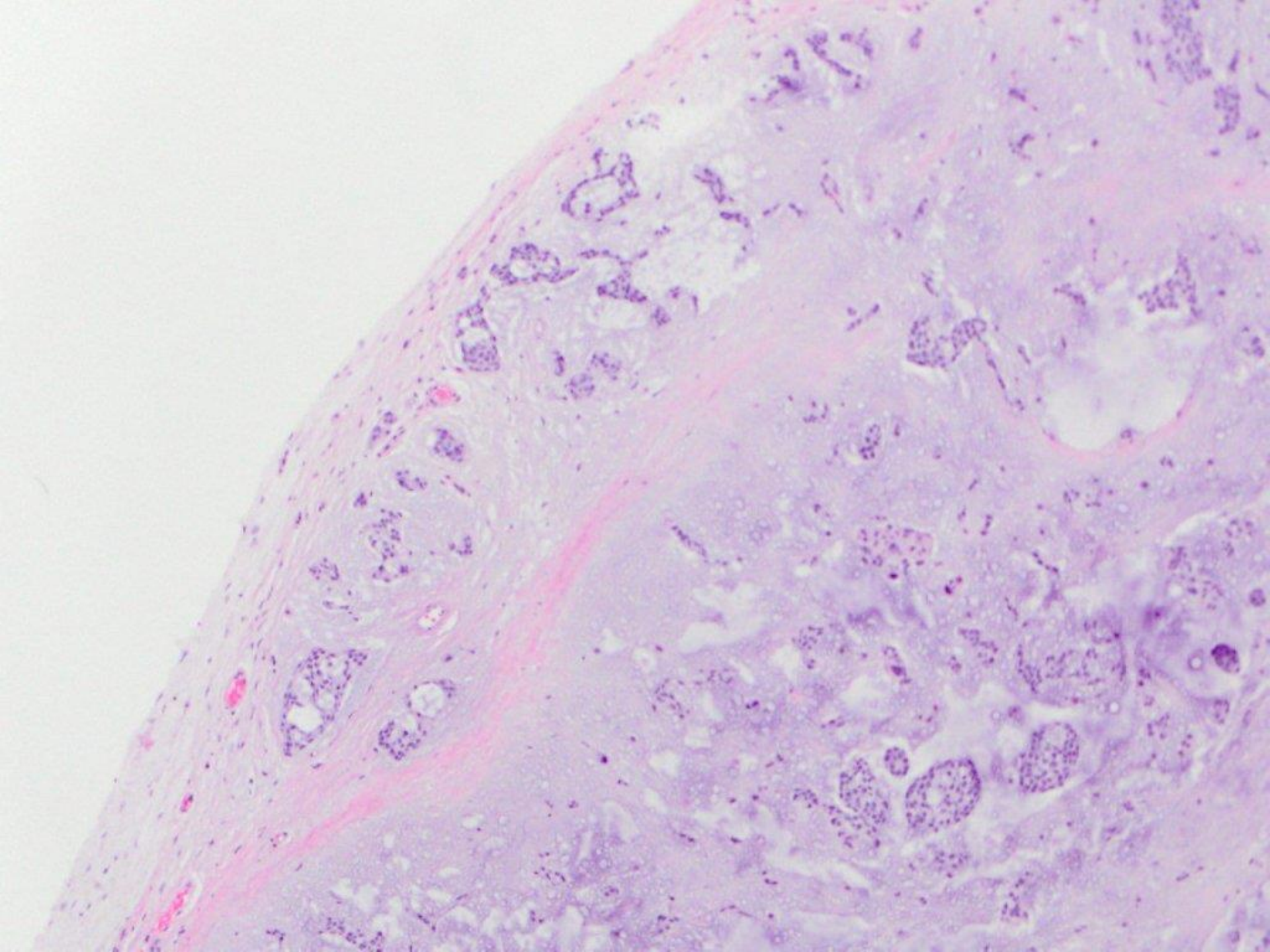
adenoid cystic carcinoma

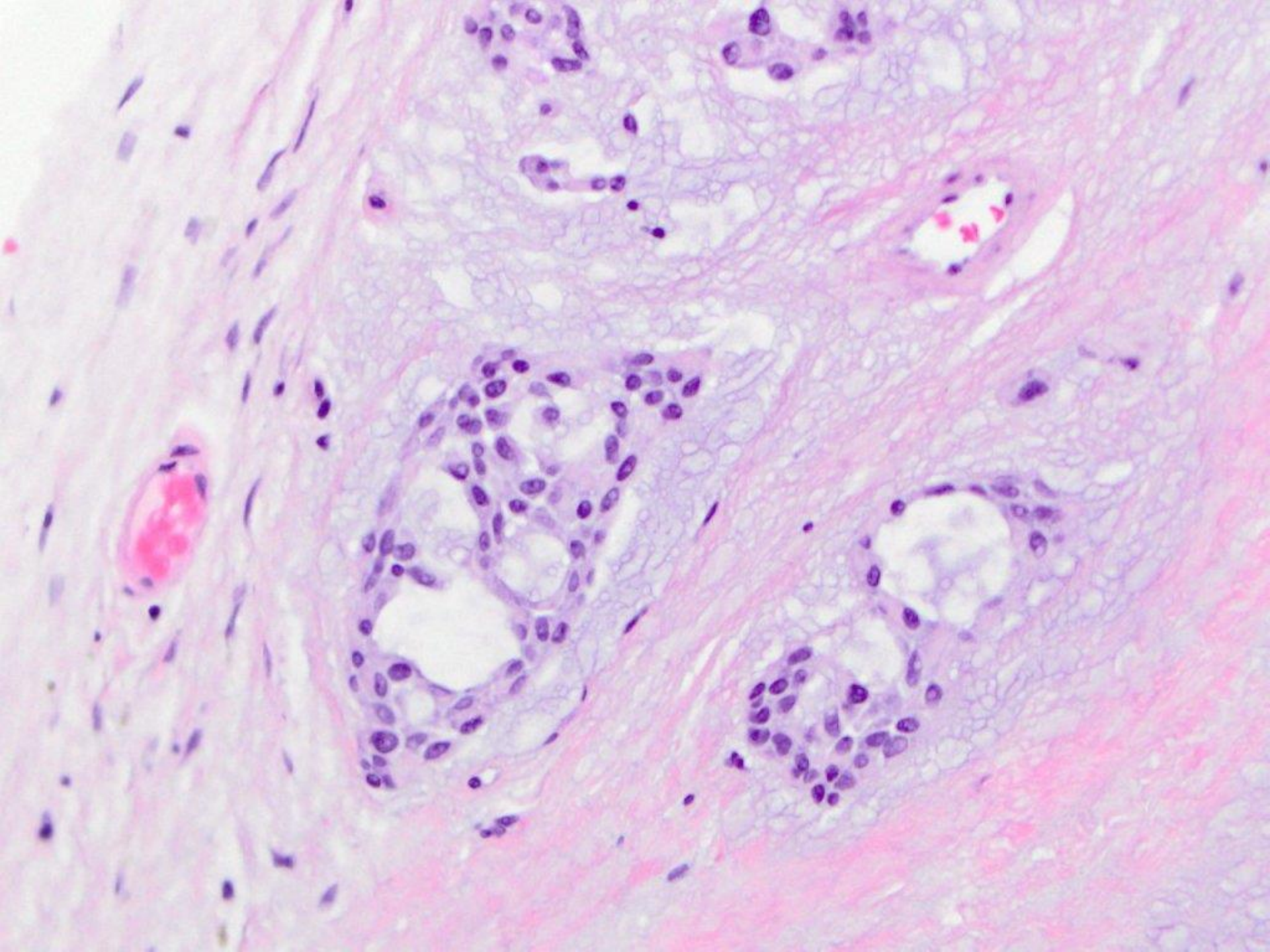


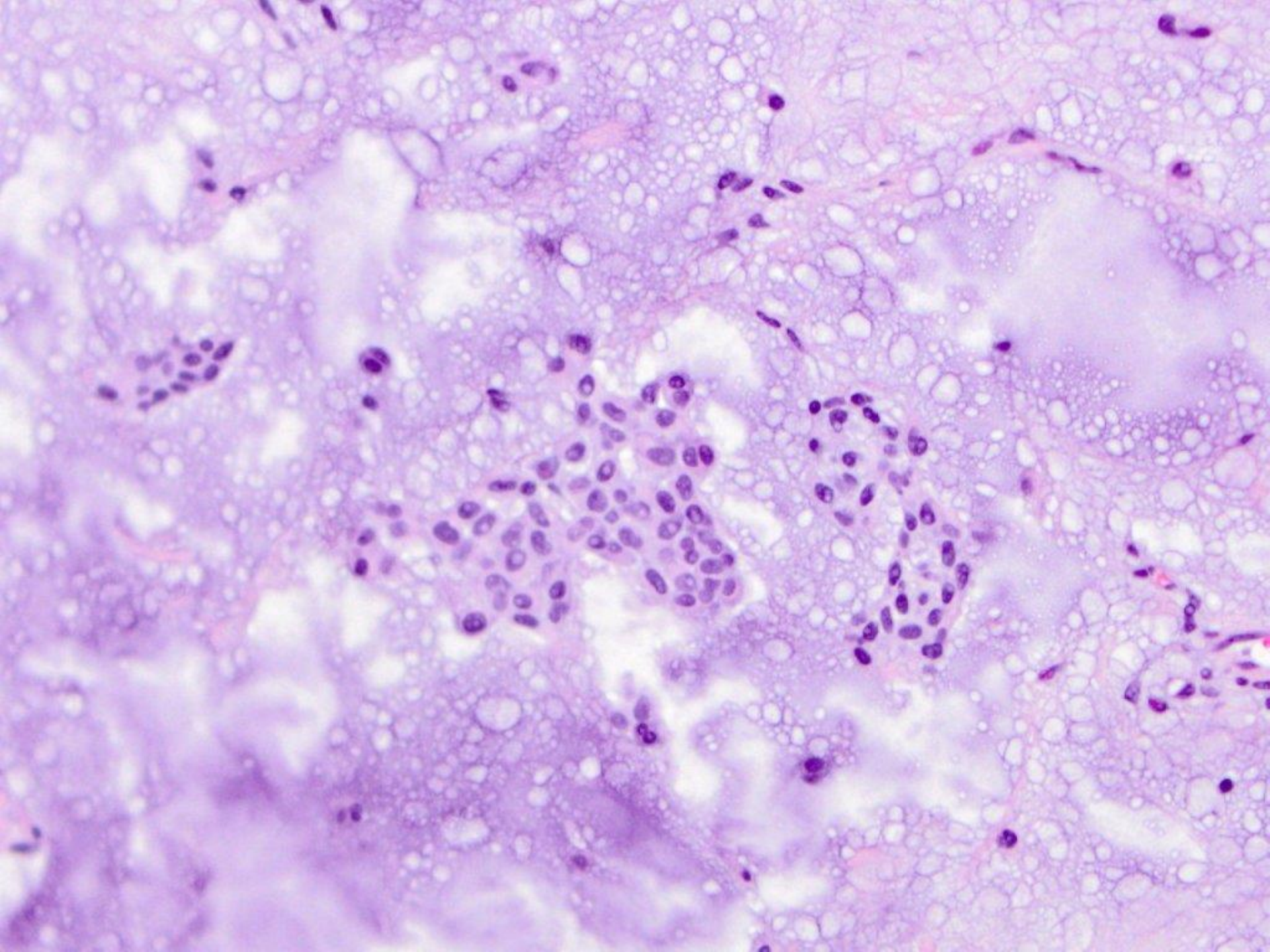


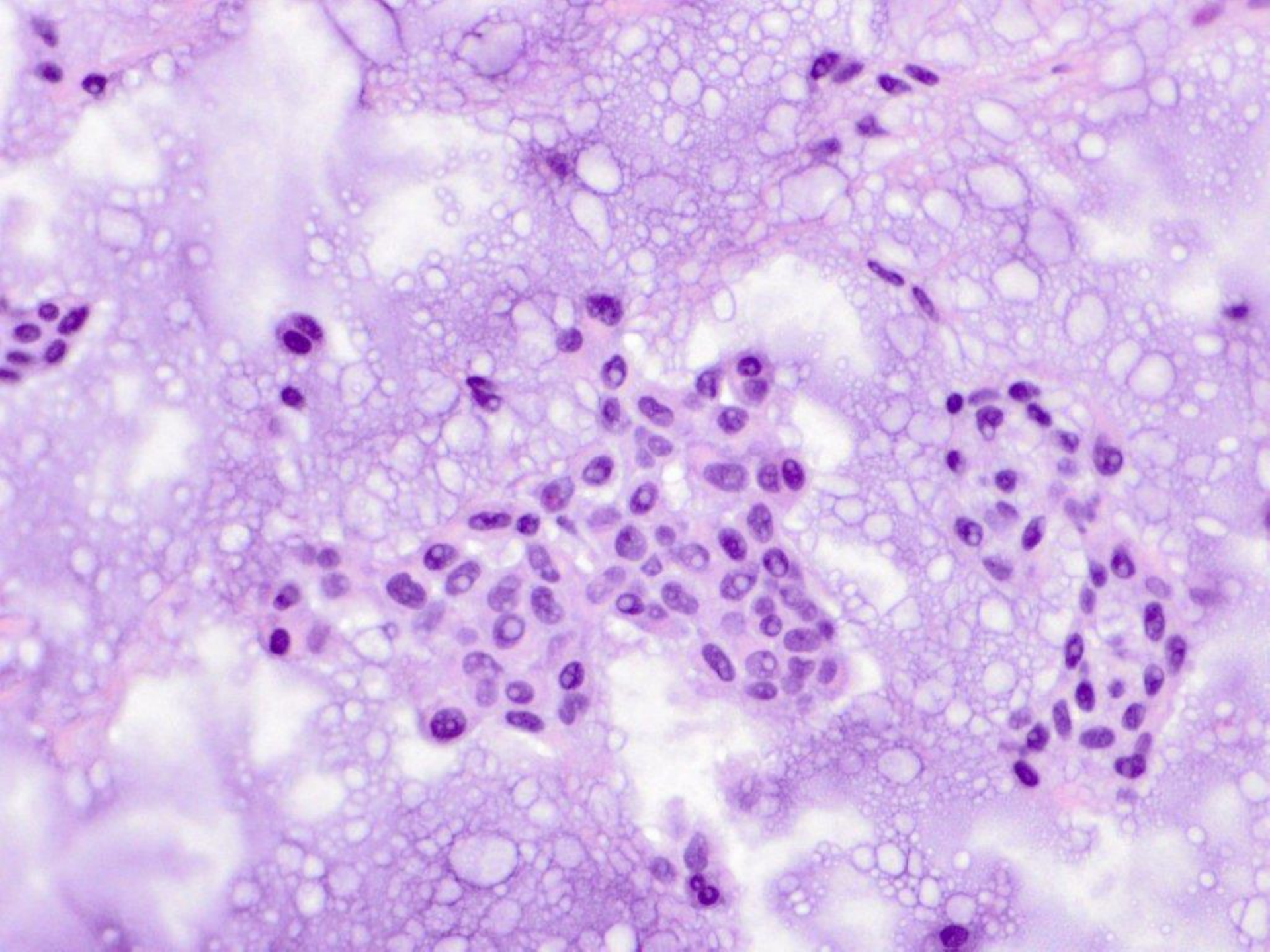


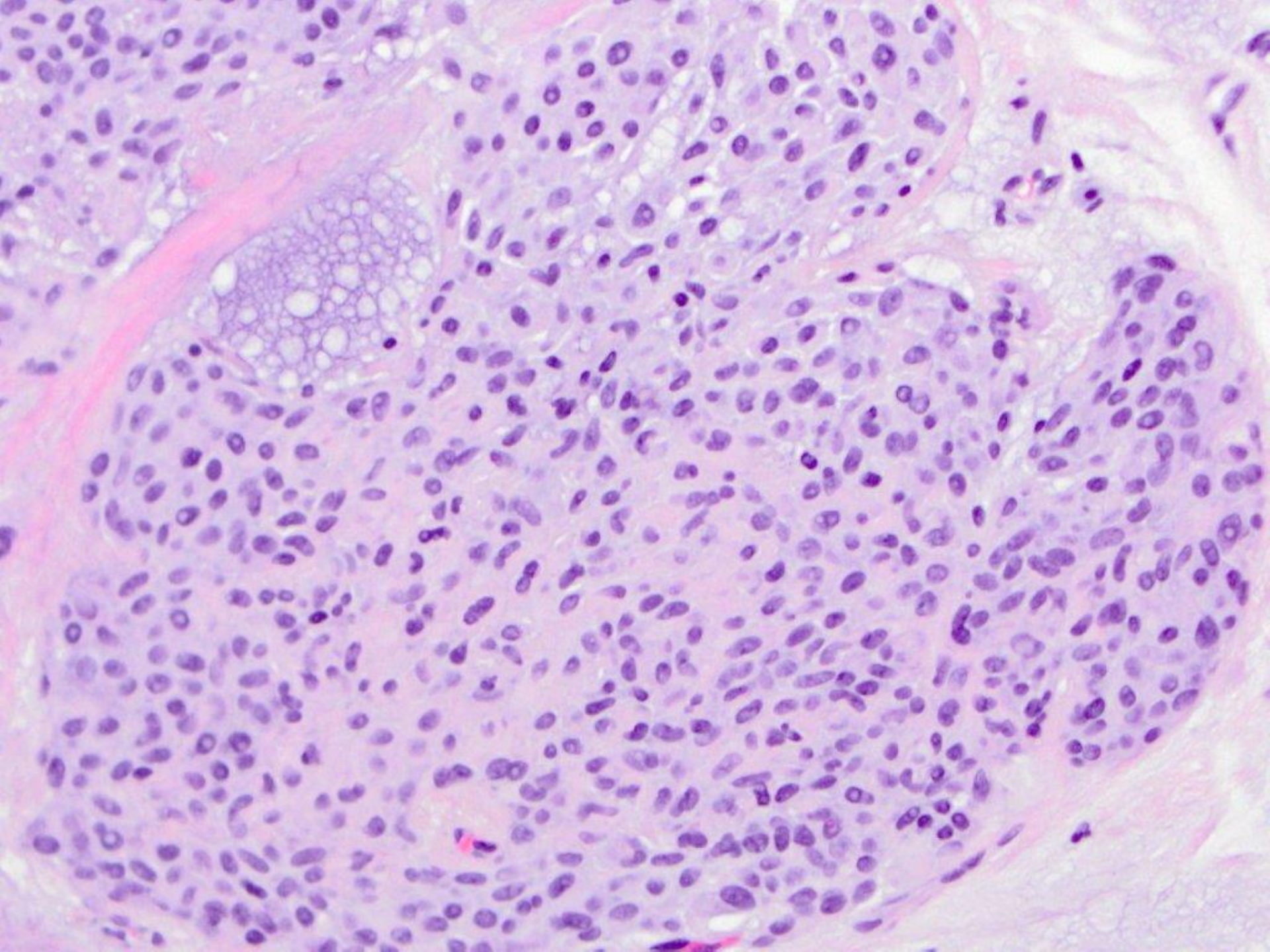


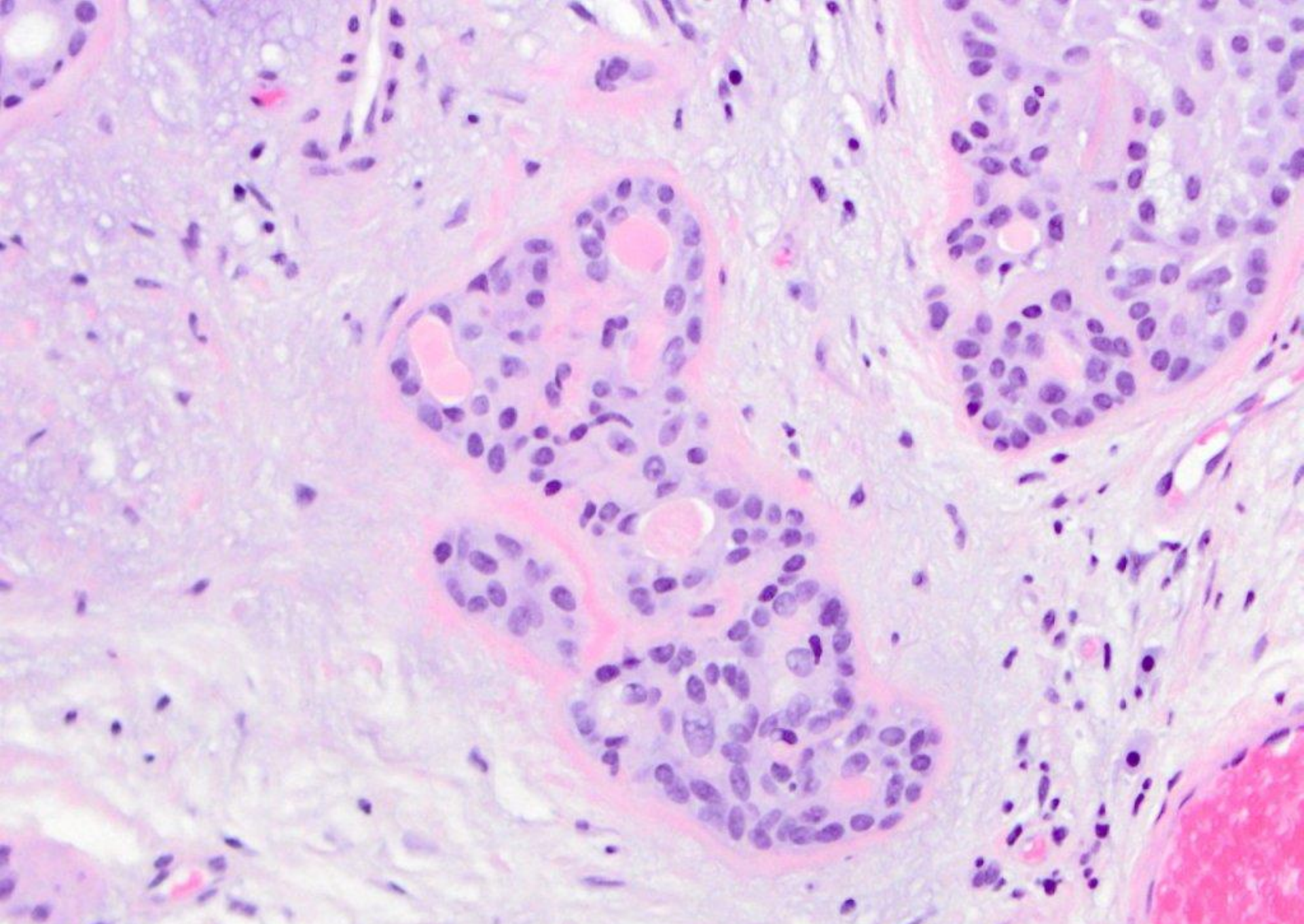




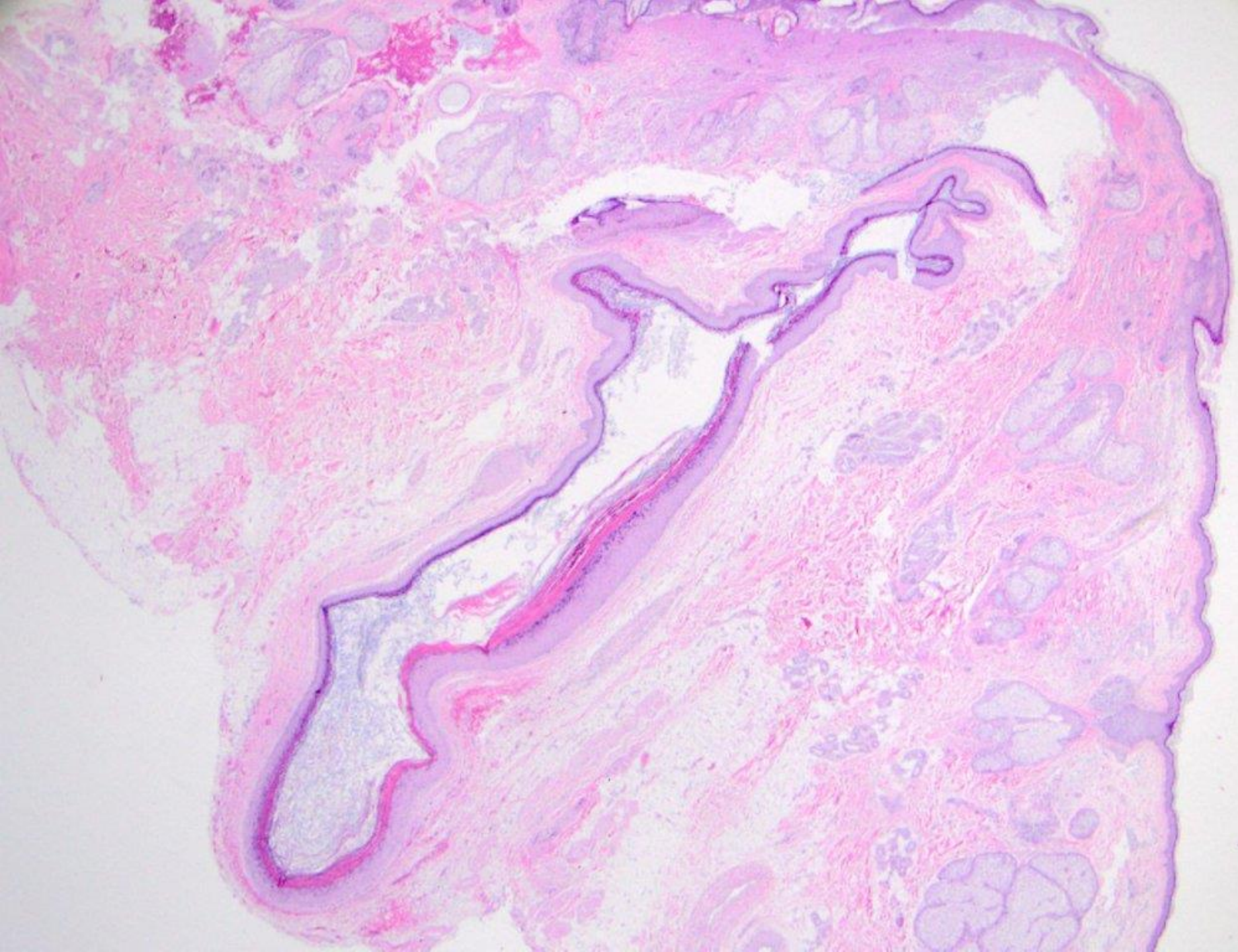


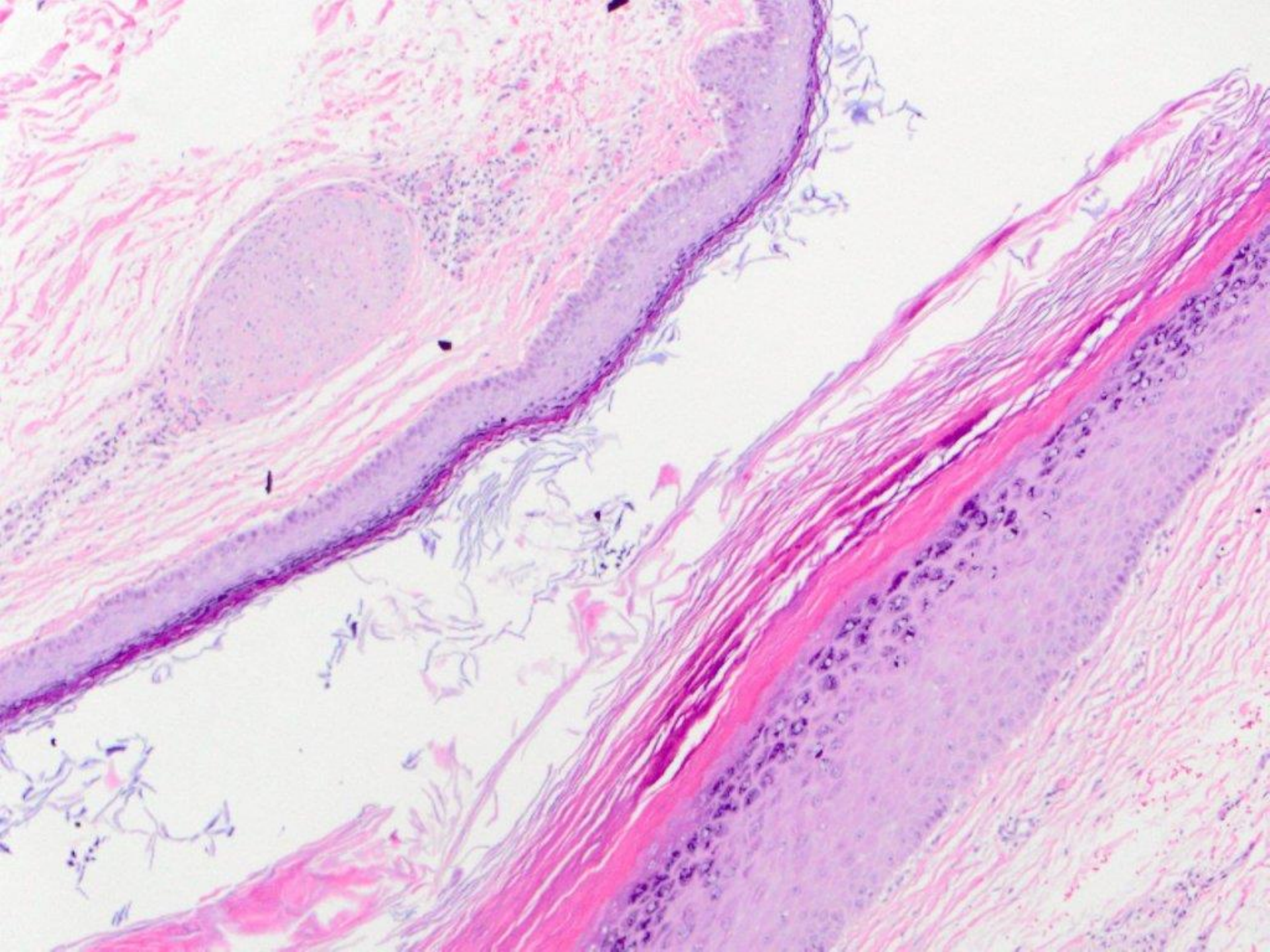




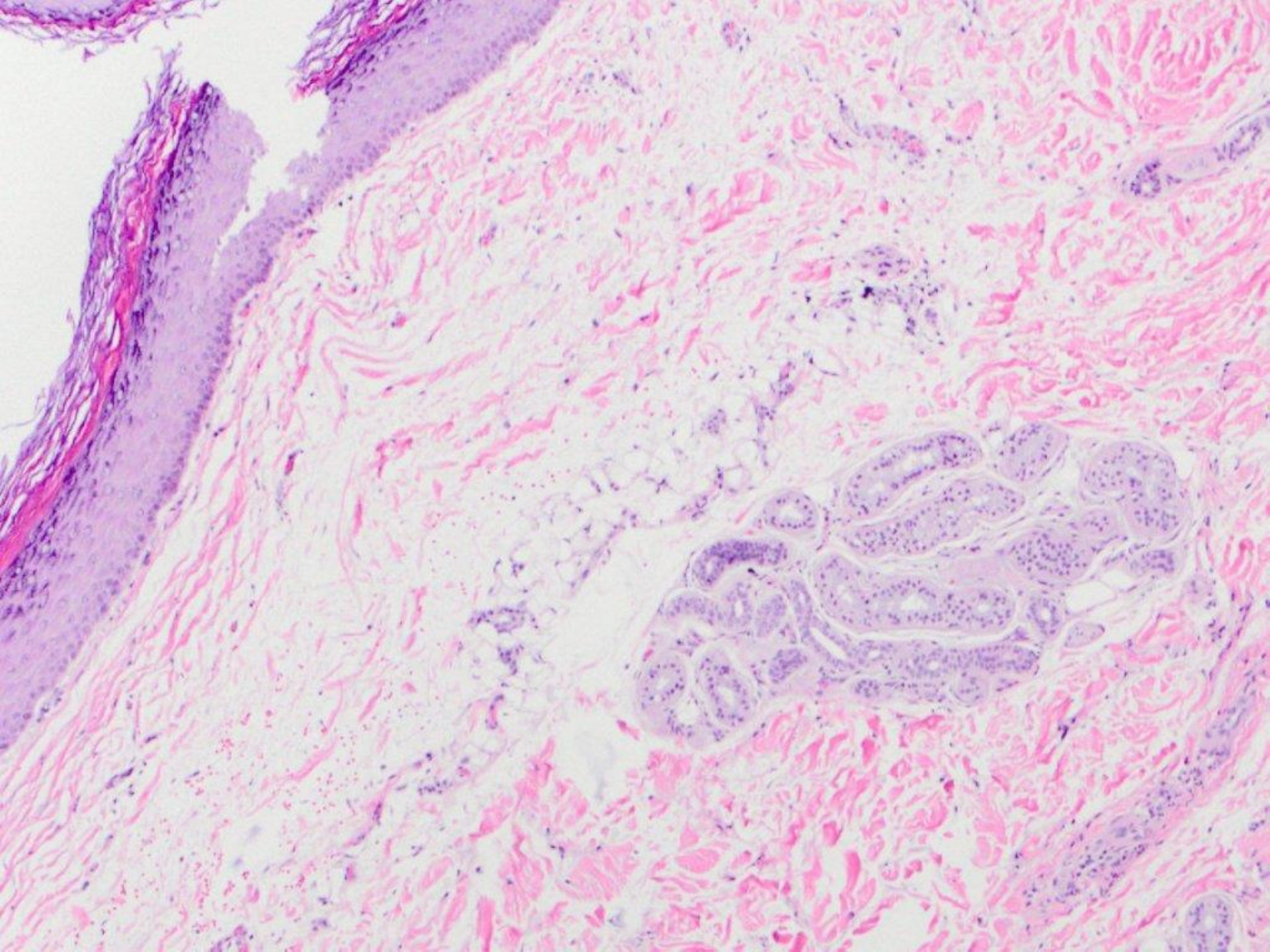


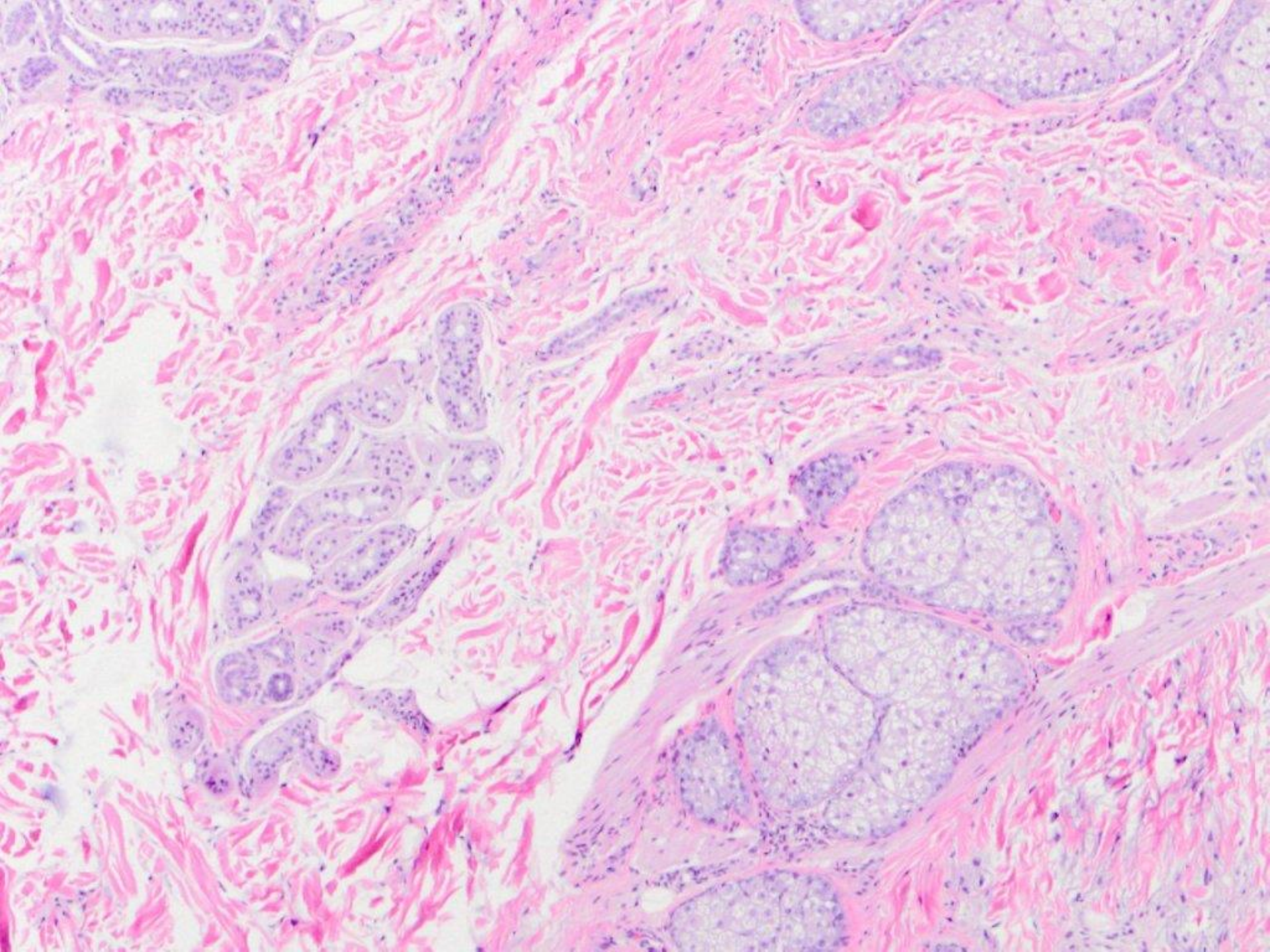
benign mixed tumor [upper lip]

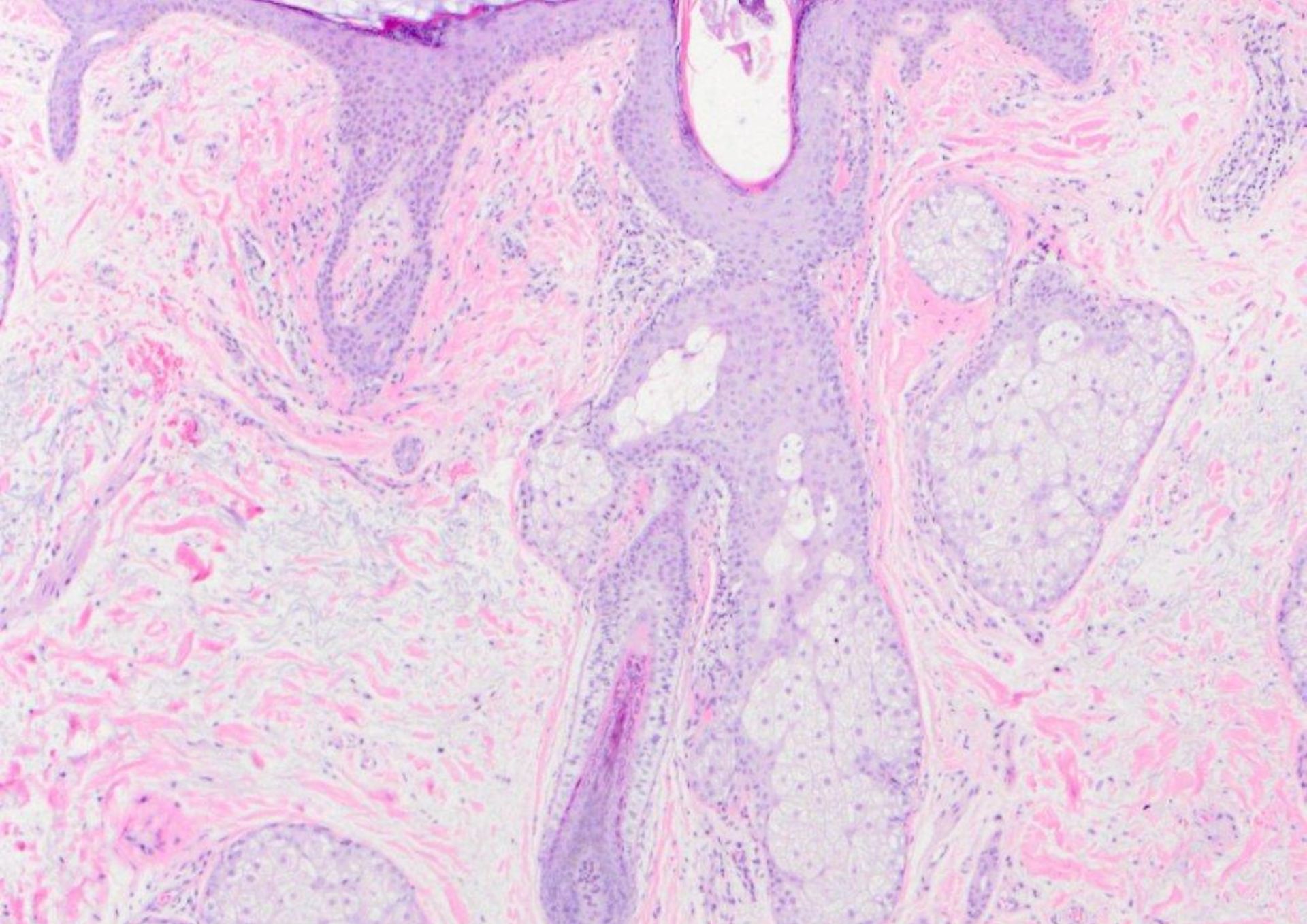




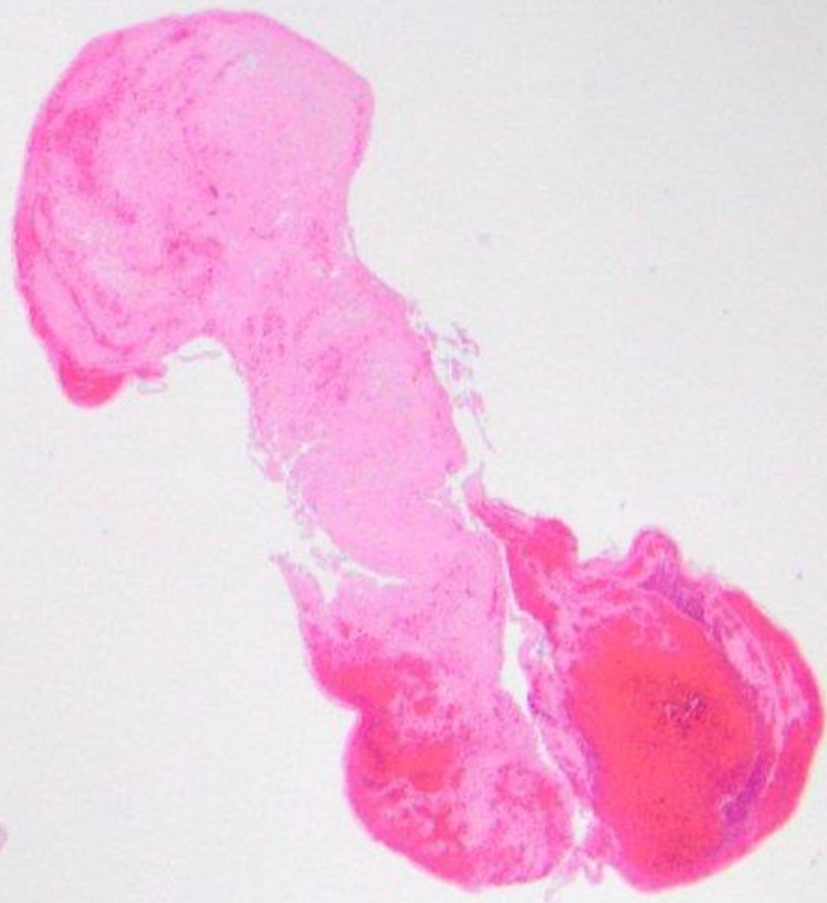
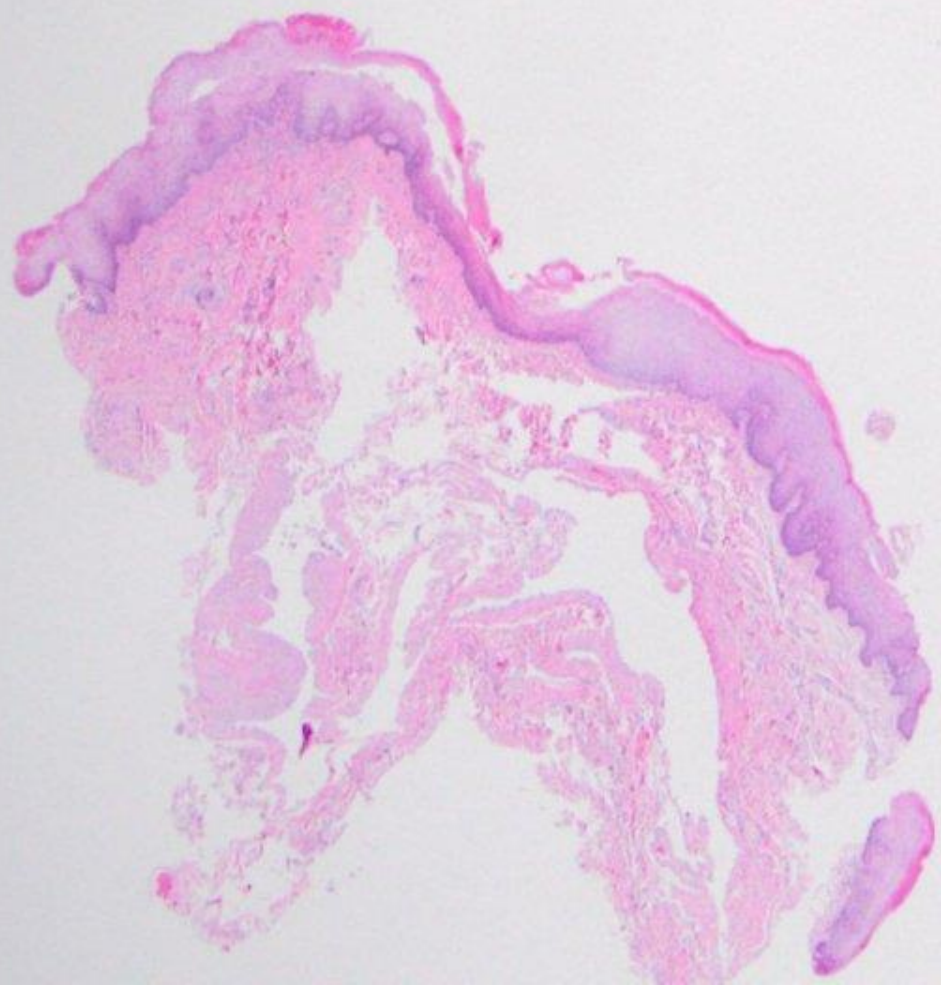


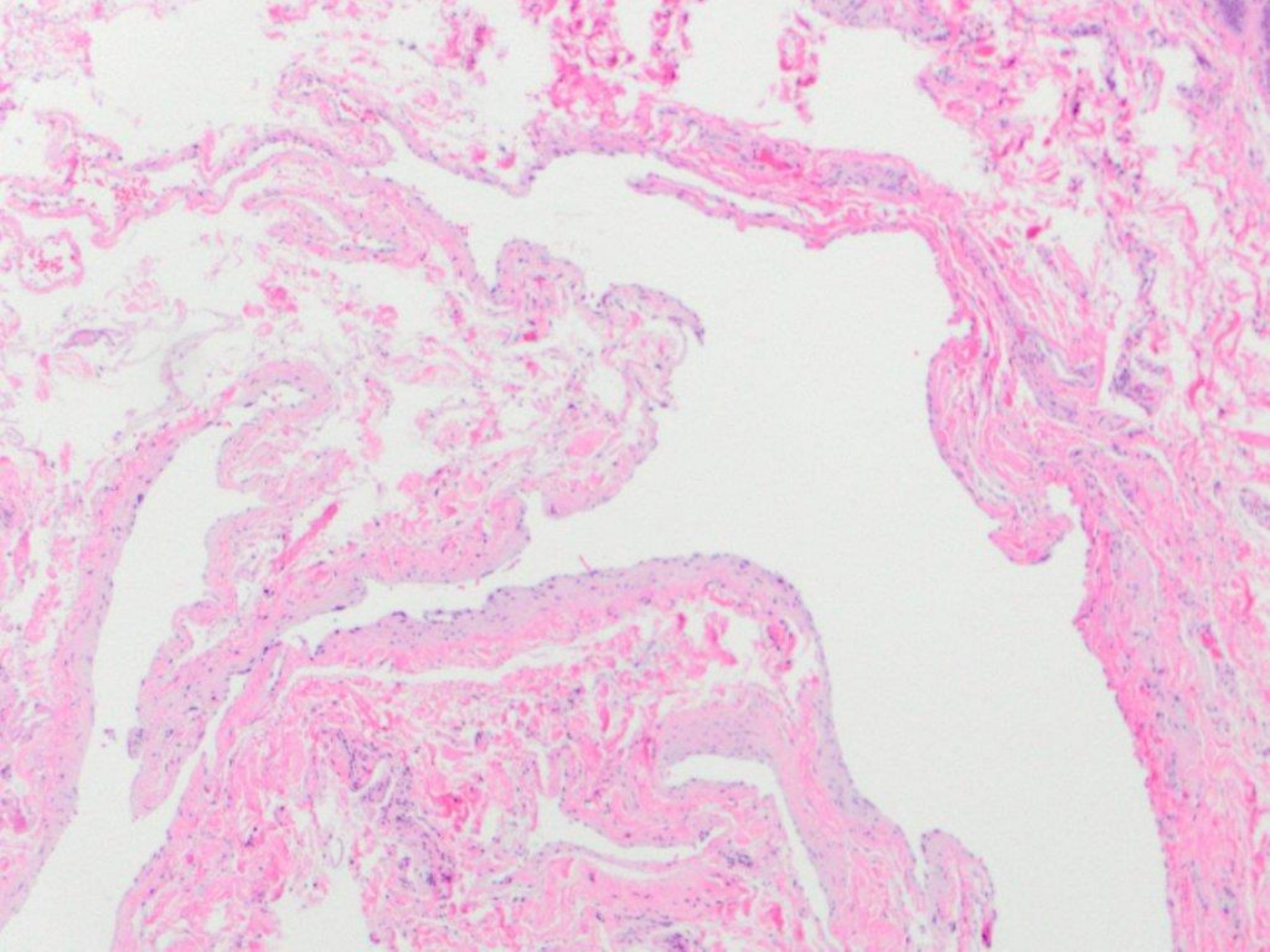


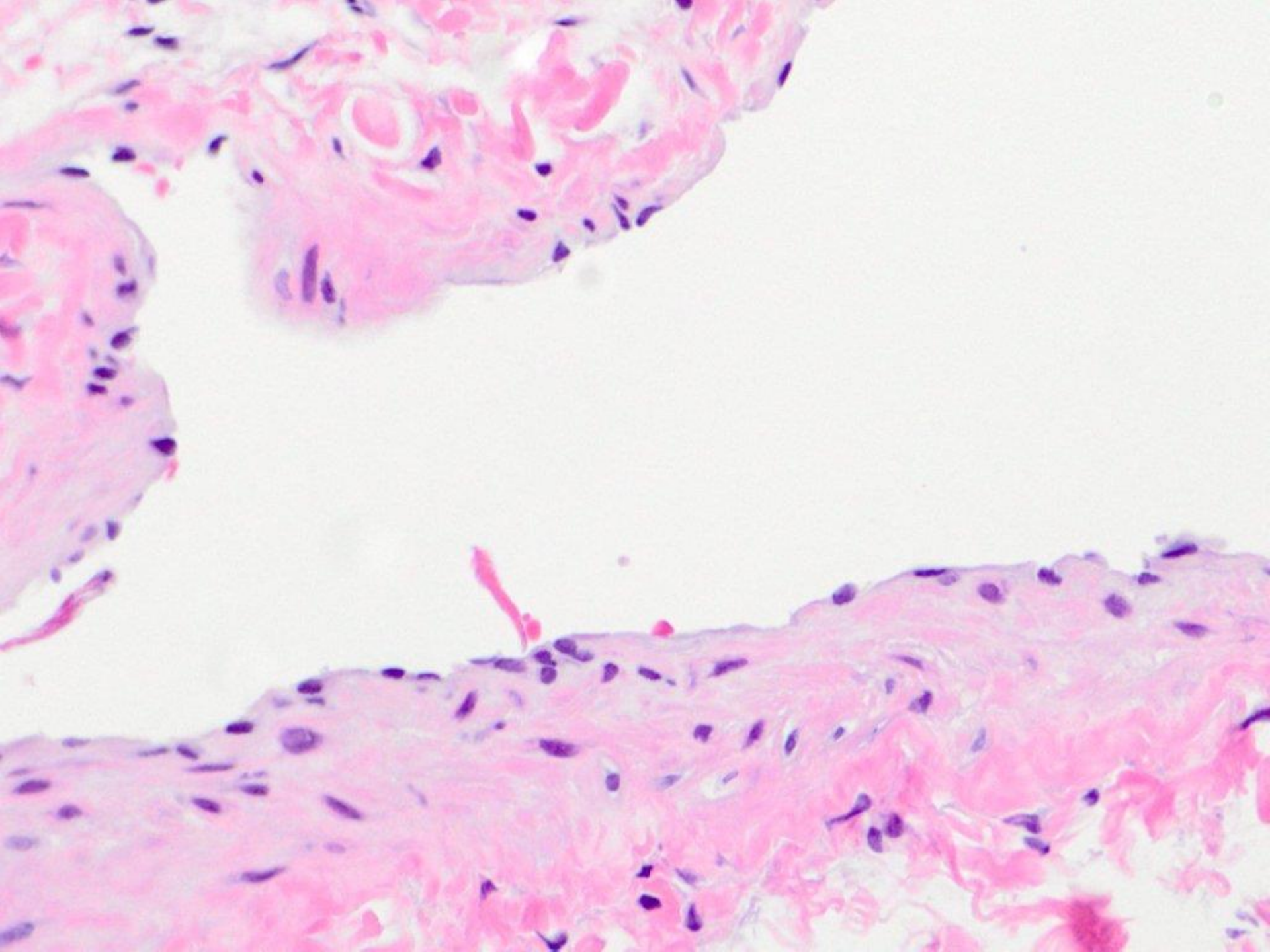


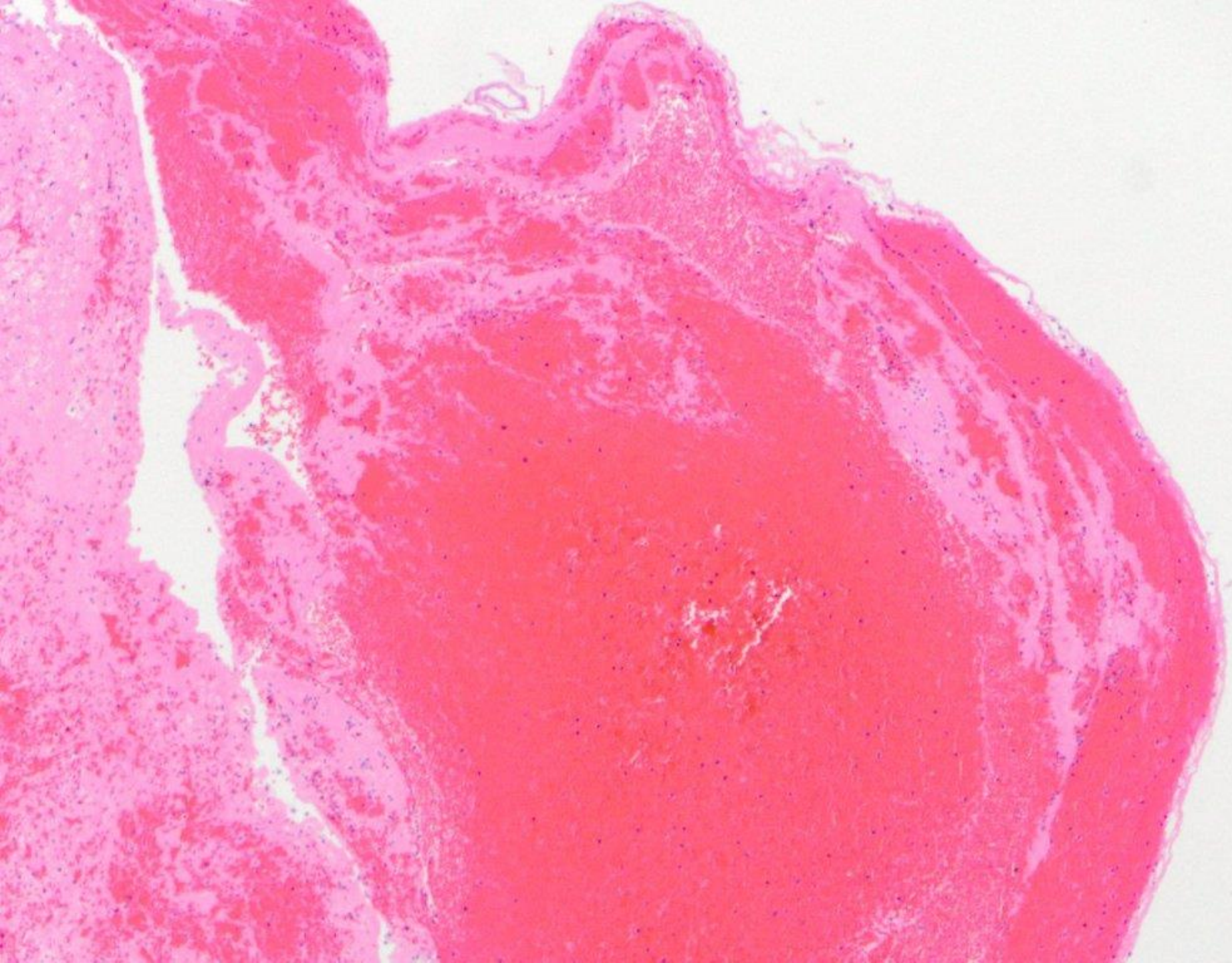


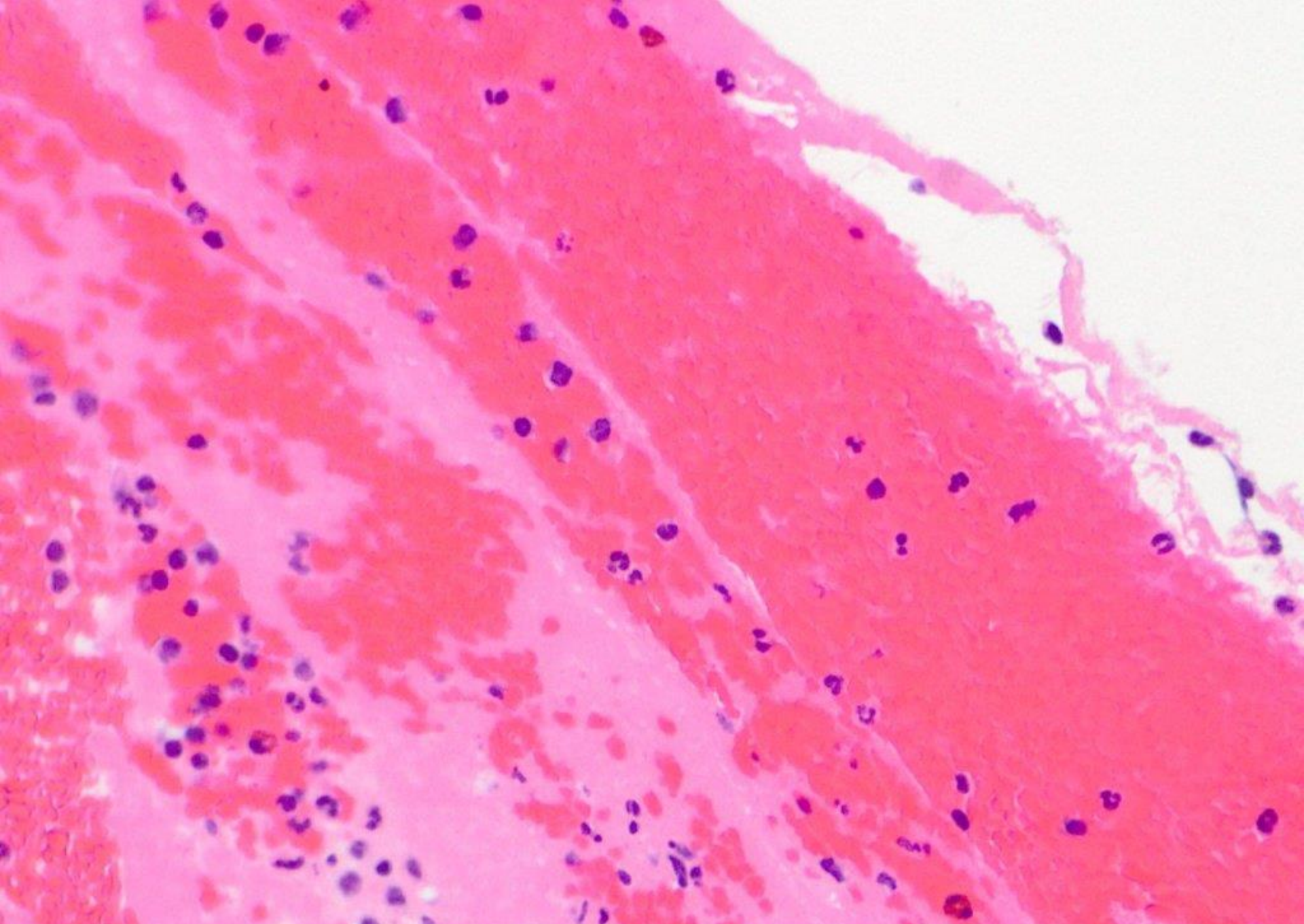
epidermoid cyst [scalp; sebaceous and eccrine elements not associated with cyst]











varix and organizing thrombus